

Clinical practice guidelines for Allied Disorders of Hirschsprung's Disease –Practical version

“Establishment of guideline including transition in pediatric intractable gastrointestinal disease” (The Ministry of Health, Labour and Welfare of Japan, Health Labour Sciences Research Grant in fiscal years 2014-2016: Tomoaki Taguchi's group).

Issue date of the first edition: June 4, 2017

Table of contents

I.	Introduction	3
II.	Guideline Summary	5
III.	List of terminology and abbreviations	9
IV.	Development organization and policy.....	11
	1. Development body	11
	1) Guideline steering committee	11
	2) Guideline development group	11
	3) Systematic review team.....	12
	4) External evaluation committee member	12
	5) Administration office for the guideline development	12
	2. Development process	13
	1) Policy	13
	2) Precautions	14
	3) Conflict of interest.....	14
	4) Funding for the development	14
V.	SCOPE	15
	1. Basic characteristics of allied disorders of Hirschsprung's disease	15
	1) Clinical characteristics of allied disorders of Hirschsprung's disease	15
	2) Epidemiological characteristics of allied disorders of Hirschsprung's disease.....	16
	3) Overall flow of clinical practice for each allied disorders of Hirschsprung's disease	16
	2. Coverage of the clinical practice guideline.....	40
	1) Within the scope of this guideline.....	40
	2) Outside of the scope of this guideline	40
	3. CQ and systematic review	40
	1) Setting of CQ	40
	2) Systematic review	40
	4. Determination of recommendations to finalization and implementation policy.....	42
	1) Determination of recommendations	42
	2) Finalization.....	43
	3) Implementation.....	43
VI.	Recommendation	49
	1.CQ1: How are isolated hypoganglionosis, MMIHS, CIIP diagnosed?	49
	2.CQ2: What kind of drug therapy is recommended for the treatment of isolated hypoganglionosis, MMIHS, and CIIP?.....	57
	3.CQ3: Is gastrointestinal decompression therapy recommended for the treatment of isolated hypoganglionosis, MMIHS, and CIIP?	64

4.CQ4: Is nutrition therapy recommended for isolated hypoganglionosis, MMIHS, and CIIP?	69
5.CQ5: Is radical surgical treatment recommended for the treatment of isolated hypoganglionosis, MMIHS, and CIIP?	75
6.CQ6: Is small bowel transplantation recommended for the treatment of isolated hypoganglionosis, MMIHS, and CIIP?	78
7.CQ7: What is the prognosis of isolated hypoganglionosis, MMIHS, and CIIP?.....	84
VII. Planning after public release	87
1. Organization after public release	87
2. Introduction	87
3. Evaluation of effectiveness	87
4. Revision.....	88

I. Introduction

Despite the presence of ganglion cells in the rectum, some cases showing symptoms and findings similar to those of Hirschsprung's disease have been recognized among pediatric surgeons. Since Ravitch described such cases as “pseudo Hirschsprung's disease” in the *Annals of Surgery* in 1958, various descriptions have been used, such as Hirschsprung's disease-related disorders, variant Hirschsprung's disease, allied disorders of Hirschsprung's disease, and Hirschsprung's disease-related neuromuscular disorders of the intestine. However, the disease concepts and the individual diseases included in the disease group have changed gradually over time. In Japan, this group of disease was initially described as “aganglionosis-related disease” in *Neonate Surgery* in 1978, and in 1988, a survey report of Pseudo-Hirschsprung's Disease and Related Disorders was released in the *Journal of the Japanese Society of Pediatric Surgeons* (Akihiro Toyosaka). In 1993, a national survey was conducted by a research group on allied Hirschsprung's diseases (Eizo Okamoto).

The development of a clinical practice guideline for allied disorders of Hirschsprung's diseases was triggered by a nationwide survey included in the “Nation-wide survey and Proposal of guideline in Hirschsprung' disease allied disorders” project supported by the Ministry of Health, Labour and Welfare of Japan (Tomoaki Taguchi's group), in fiscal year 2011. The disease concept, classification, diagnostic criteria, and classification of severity were determined by the “Comprehensive investigation and establishment of guideline in pediatric intractable hepato-gastrointestinal disease” (Tomoaki Taguchi's group) in 2012-2013. The development of a clinical practice guideline for allied disorders of Hirschsprung's disease was continued by the “Establishment of guideline including transition in pediatric intractable gastrointestinal disease” (Tomoaki Taguchi's group) in 2014-2016, and the guideline has now been released. Pediatric surgeons, pediatricians, pathologists, and others repeatedly discussed the disease concept, classification, and how to treat chronic idiopathic intestinal pseudo-obstruction. With the participation of Dr. Atsushi Nakajima from the adult domain of the research group for chronic idiopathic intestinal pseudo-obstruction, guidelines spanning such diseases from childhood to adulthood were successfully released.

With the cooperation of many people, three of the seven known allied disorders of Hirschsprung's disease isolated hypoganglionosis, megacystis-microcolon-intestinal hypoperistalsis syndrome, and chronic idiopathic intestinal pseudo-obstruction were officially certified as intractable diseases by the Ministry of Health, Labor and Welfare of Japan. We have had to employ unique methods to develop these clinical practice guideline, as high quality evidence is limited for these intractable diseases due to the few cases available for evaluation, the unknown etiology, and the lack of any established treatments. Fortunately, the doctors in Medical Information Network Distribution System (Minds) understood the situation and kindly provided careful guidance throughout the project. I sincerely appreciate the great support and efforts made by the systematic review team, who examined hundreds of domestic and international articles in detail in a short period of time, creating the evidence tables and Systematic Review reports by organizing the findings corresponding to each Clinical Question. This evidence table is

now the core of this guideline, and I hope it will serve as a useful document for clinical and research practice. Experts in the guideline development team created the recommendations in a short period of time. These efforts by the research members are greatly appreciated and were thoroughly vetted in external evaluation by Dr. Toshio Morizane. I hope that this clinical practice guideline will prove useful for both daily clinical practice as well as future studies.

I would like to pay my respect and show my gratitude to Dr. Tomoaki Taguchi for his strong leadership throughout this research project.

June 4, 2017

Japanese Study Group of Allied Disorders of Hirschsprung's Disease
Guideline development group

Hiroshi Matsufuji

II. Guideline Summary

CQ1: How are isolated hypoganglionosis, MMIHS, and CIIP diagnosed?

CQ1-1	How is isolated hypoganglionosis diagnosed?
Recommendation	A full-thickness biopsy of the gastrointestinal tract (especially the small intestine and sigmoid colon) is recommended for the definitive diagnosis of isolated hypoganglionosis. [1C]

CQ1-2	How is megacystis-microcolon-intestinal hypoperistalsis syndrome (MMIHS) diagnosed?
Recommendation	For cases in which symptoms of bowel obstruction, such as abdominal distension and vomiting, are present during the neonatal period and no organic obstruction is observed, a gastrointestinal series is recommended. When a microcolon is observed and megalocystis is simultaneously confirmed by cystography or computed tomography (CT)/ultrasonography, MMIHS is strongly suspected. An intestinal full-thickness biopsy is recommended for the definitive diagnosis to differentiate it from other allied Hirschsprung's diseases. [1C]

CQ1-3	How is chronic idiopathic intestinal pseudo-obstruction (CIIP) diagnosed?
Recommendation	The duration of symptoms and the bowel obstruction conditions are determined from the clinical history and physical examination findings. The presence of intestinal dilatation, air-fluid level formation, and the absence of mechanical obstruction are confirmed by diagnostic imaging. For children, an intestinal full-thickness biopsy is recommended for the definitive diagnosis to differentiate it from other allied Hirschsprung's diseases. For adults, it is important to differentiate true mechanical obstruction and secondary intestinal pseudo-obstruction, and a full-thickness biopsy is not conducted as it is for children. [1D]

CQ2: What kind of drug therapy is recommended for the treatment of isolated hypoganglionosis, MMIHS, and CIIP?

CQ2-1	What kind of drug therapy is recommended for the treatment of isolated hypoganglionosis?
Recommendation	No drug therapy is recommended for isolated hypoganglionosis at this point. [D]

CQ2-2	What kind of drug therapy is recommended for the treatment of megacystis-microcolon-intestinal hypoperistalsis syndrome (MMIHS)?
Recommendation	Although the usefulness of Chinese medicines (Daikenchuto) or probiotics has been reported as drug therapy for MMIHS, evidence is insufficient to recommend these therapies at present. [D]

CQ2-3	What kind of drug therapy is recommended for the treatment of chronic idiopathic intestinal pseudo-obstruction (CIIP)?
Recommendation	As drug therapies for CIIP, prucalopride, cisapride, Chinese medicines (Daikenchuto), probiotics, and antibiotic (erythromycin) are sometimes used, and some reports have shown the usefulness of those agents for functional

	gastrointestinal disorder or abdominal symptoms. However, evidence is insufficient to recommend these therapies at present. [D]
--	---

CQ3: Is gastrointestinal decompression therapy recommended for the treatment of isolated hypoganglionosis, MMIHS, and CIIP?

CQ3-1	Is gastrointestinal decompression therapy recommended for the treatment of isolated hypoganglionosis?
Recommendation	Upper jejunostomy is proposed for isolated hypoganglionosis. Ileostomy may be effective in some cases, but the efficacy of enterostomy at any other part of the intestinal tract is unknown. [2C]

CQ3-2	Is gastrointestinal decompression therapy useful for the treatment of megacystis-microcolon-intestinal hypoperistalsis syndrome (MMIHS)?
Recommendation	No evidence supports the positive recommendation of gastrointestinal decompression for MMIHS. [D]

CQ3-3	Is gastrointestinal decompression useful for the treatment of chronic idiopathic intestinal pseudo-obstruction (CIIP)?
Recommendation	Intermittent decompression via enteric tube may be effective in some CIIP cases, and enterostomy may be effective in other cases. The appropriate approach should be considered on a case-by-case basis. [2D]

CQ4: Is nutritional therapy recommended for isolated hypoganglionosis, MMIHS, and CIIP?

CQ4-1	Are enteral nutrition and parenteral nutrition useful as nutritional therapies for isolated hypoganglionosis?
Recommendation	Enteral nutrition and parenteral nutrition are recommended as nutritional therapies for isolated hypoganglionosis. [1D]

CQ4-2	Are enteral nutrition and parenteral nutrition useful as nutritional therapies for megacystis-microcolon-intestinal hypoperistalsis syndrome (MMIHS)?
Recommendation	Enteral nutrition and parenteral nutrition are recommended as nutritional therapies for MMIHS. [1D]

CQ4-3	Are enteral nutrition and parenteral nutrition useful as nutritional therapies for chronic idiopathic intestinal pseudo-obstruction (CIIP)?
Recommendation	Enteral nutrition and parenteral nutrition are recommended as nutritional therapies for CIIP. [1D]

CQ5: Is radical surgical treatment recommended for the treatment of isolated hypoganglionosis, MMIHS, and CIIP?

CQ5-1	Is radical surgical treatment (other than stoma construction) recommended for the treatment of isolated hypoganglionosis?
Recommendation	Avoiding radical surgical treatment is proposed. [2C]

CQ5-2	Is radical surgical treatment (other than stoma construction) recommended for the treatment of megacystis-microcolon-intestinal hypoperistalsis syndrome (MMIHS)?
Recommendation	Resection of dilated intestines does not improve ileus symptoms in MMIHS, so avoiding radical surgical treatment is proposed. [2D]

CQ5-3	Is radical surgical treatment (other than stoma construction) recommended for the treatment of chronic idiopathic intestinal pseudo-obstruction (CIIP)?
Recommendation	Concomitant use of antegrade continence enema and antidromic enema is proposed for the treatment of CIIP to improve defecation. [2D] In cases with duodenal dilatation, duodenojejunostomy is proposed to improve the intestinal transit. It may relieve the pseudo-obstructive symptoms to some extent. [2D] Intestinal resection dose not improve the pseudo-obstructive symptoms, so avoiding radical surgical treatment is proposed. [2D]

CQ6: Is small bowel transplantation recommended for the treatment of isolated hypoganglionosis, MMIHS, and CIIP?

CQ6-1	Is small bowel transplantation useful for the treatment of isolated hypoganglionosis?
Recommendation	Small bowel transplantation is proposed for the treatment of isolated hypoganglionosis, as it may be useful for the following cases: patients in whom discontinuing parenteral nutrition (PN) is difficult even after the maximum use of the native intestinal tract under intestinal rehabilitation; patients in whom the number of central venous access routes is lacking; patients with repeated episodes of sepsis; and patients with progressive hepatopathy. [2D]

CQ6-2	Is small bowel transplantation useful for the treatment of megacystis-microcolon-intestinal hypoperistalsis syndrome (MMIHS)?
Recommendation	Isolated small bowel transplantation is proposed for cases not complicated with liver or renal failure. [2D] Multiple organ transplantation is proposed for cases complicated with liver or renal failure. [2D]

CQ6-3	Is small bowel transplantation useful for the treatment of chronic idiopathic intestinal pseudo-obstruction (CIIP)?
Recommendation	Small bowel transplantation for the treatment of CIIP is proposed, as it may be useful for the following cases: patients whose symptoms remain intolerable even with adequate parenteral nutrition, enteral nutrition, and gastrointestinal decompression therapy; patients in whom the number of central venous access routes is lacking; and patients with repeated episodes of sepsis. The possible impairment of the native gastric outlet function needs to be considered when small bowel transplantation is planned and performed. [2D]

CQ7: What is the prognosis of isolated hypoganglionosis, MMIHS, and CIIP?

CQ7-1	What is the prognosis of isolated hypoganglionosis?
-------	---

Recommendation	Long-term survival can be expected with appropriate treatment. In many cases, adequate nutritional support and intestinal stoma care are required for a long period of time. [C]
----------------	--

CQ7-2	What is the prognosis of megacystis-microcolon-intestinal hypoperistalsis syndrome (MMIHS)?
Recommendation	Patients with MMIHS have a poor prognosis in comparison to healthy children; however, long-term survival can be expected with appropriate treatment. In many cases, adequate nutritional support and intestinal stoma care are required, and the functional prognosis is poorer than that of healthy children. [C]

CQ7-3	What is the prognosis of chronic idiopathic intestinal pseudo-obstruction (CIIP)?
Recommendation	The actual prognosis of CIIP developed in childhood is not poor; however, adequate nutritional support and intestinal stoma care are required for a long period in many cases. The functional prognosis of CIIP is poor. [C]

III. List of terminology and abbreviations

Terminology	Abbreviation	Description
Hypoganglionosis		A state of having a small number of intestinal ganglion cells. In Europe and the US, it may refer to the transitional zone of Hirschsprung's disease.
Acetylcholinesterase staining	AchE staining	An enzymatic staining method. In the aganglionic intestine of Hirschsprung's disease, positive nerve fibers can be seen to be growing with such staining.
Transitional segment/transitional zone		Site between the aganglionic intestinal segment of Hirschsprung's disease and the normal intestine. The number of ganglion cells is not sufficient in this zone. It may be described as "Hypoganglionosis".
Pseudo-obstruction		A state of bowel obstruction without mechanical obstruction of the intestinal lumen.
Air-fluid level / niveau		An image seen with bowel obstruction, presented as a sharp flat horizontal line representing the interface between gas density above and fluid density below in the intestinal tract.
Megacystis-microcolon-intestinal hypoperistalsis syndrome	MMIHS	An allied Hirschsprung's disease.
Clinical question	CQ	Clinically asked questions concerning various aspects of a disease, such as the condition, evaluation, treatment, risk, and prophylaxis. Organized by formulation with four elements (Patient, Intervention, Comparison, Outcome; PICO) to facilitate literature searches.
Enteral nutrition		A method of injecting liquid food and nourishing diet into the stomach or small intestine directly when food cannot be taken orally. Injected through a tube, gastrostomy, or enterostomy.
Systematic review	SR	A review using systematic and explicit methods to select and analyze collected data from high-quality studies, such as randomized controlled trials (RCTs).
Atresia of small bowel/small intestinal atresia		An intestinal blockage caused by a reduced blood supply due to volvulus or intussusception in the fetal stage.
Intestinal decompression		To drainage the gastrointestinal contents via enterostomy, gastrostomy, naso-gastric tube, long tube, or trans-anal tube in order to relieve intragastric pressure.
Manometry/intestinal manometric study		An examination to evaluate the presence of a normal pattern of intestinal motility by measuring the intragastric pressure. The object of the examination is to perceive the disease and its pathology and evaluate the motility function before and after surgical treatment.
Parental nutrition, intravenous alimentation		A technique providing nutrition intravenously. Intravenous nutrients are injected into a peripheral vein, higher-concentrated nutrients are directly infused into the central vein near the heart.
Neural ganglion/neural plexus		A thick node where peripheral nerve cells and nerve fibers come together. In the intestinal tracts, it consists of multiple nerve cells and glia cells.
Stoma/intestinal stoma		An opening in the intestinal tract created on the abdominal wall to excrete stool due to intestinal tract disease.
Peristalsis		Movements of the intestinal tract made by contraction and relaxation of the smooth muscle. This movement mixes, breaks, and transfers the gastrointestinal contents (food).
Microcolon		Unused colon smaller in diameter and length than the normal colon. It is a consequence of a reduced colonic capacity due to congenital proximal intestinal obstruction and is different from structural abnormalities of the colon.
Intestinal ganglion cell/enteric ganglion cell		Nerve cells present in the intestinal tract. Multiple nerve (ganglion) cells form an intestinal neural ganglion (plexus).
Isolated hypoganglionosis		An allied Hirschsprung's disease. In such cases, the number of intestinal ganglion cells is small. To distinguish this disease from the transitional segment of Hirschsprung's disease (hypoganglionosis), it is described as isolated hypoganglionosis.
Intestinal neuronal dysplasia	IND	An allied Hirschsprung's disease.
Segmental dilatation of intestine		An allied Hirschsprung's disease.
Bowel obstruction		A state that consists of mechanical blockage of the intestinal lumen and functional blockage of the bowel stream (paralytic ileus) due to reduced peristalsis.
Recto-anal inhibitory reflex/recto anal reflex/recto internal anal sphincter inhibitory reflex	RAR/ RAIR	A reflex response of relaxation of the internal anal sphincter followed by distention stimulation of the rectum. Patients with Hirschsprung's disease lack the response.

Rectal mucosal biopsy		An examination collecting a small part of the rectal mucosa for a pathological diagnosis. Acetylcholinesterase staining is used for the differentiation of Hirschsprung's disease.
Internal anal sphincter achalasia	IASA	An allied Hirschsprung's disease. The recto internal anal sphincter reflex is lacking, but ganglion cells exist in the rectum.
Aganglionosis		Used synonymously with Hirschsprung's disease. A state of lacking ganglion cells in the intestinal tract.
Bacterial translocation		A state in which enteric bacteria or bacterial products move across the intestinal membrane and emerge either in the lymphatics or the visceral circulation, causing infection. Sometimes observed when the intestinal mucosal defense system is ruined, when systemic and/or local immunity is compromised, or when intestinal bacterial overgrowth is present with motility disorder.
Hirschsprung's disease, congenital megacolon	HIRS/H disease/HD	Peristaltic disorders, bowel obstruction, and constipation are caused by the congenital absence of intestinal ganglion cells at the distal side of the intestinal tract. It is also called congenital megacolon, as the normal colon at the oral side of the aganglionic segment is dilated secondarily.
Allied disorders of Hirschsprung's disease		A group of diseases with conditions similar to Hirschsprung's diseases despite the presence of intestinal ganglion cells.
Immaturity of ganglia		An allied Hirschsprung's disease. Bowel obstructive symptom is evoked due to immature intestinal ganglion cells.
Chronic intestinal pseudo-obstruction	CIPO/CIP	A generic term of pseudo-obstruction resulting in chronic course. It is categorized into "primary", which has a cause in the intestinal tract itself, "secondary", which is related to systemic illness or drugs, and "idiopathic" with an unknown etiology.
Chronic idiopathic intestinal pseudo-obstruction	CIIP	Idiopathic (cryptogenic) type of chronic intestinal pseudo-obstruction. An allied Hirschsprung's disease.

IV. Development organization and policy

1. Development body

“Establishment of guideline including transition in pediatric intractable gastrointestinal disease” (The Ministry of Health, Labour and Welfare of Japan, Health Labour Sciences Research Grant in fiscal years 2014-2016: Tomoaki Taguchi’s group)

Japanese Study Group of Allied Disorders of Hirschsprung’s Disease

1) Guideline steering committee

Tomoaki Taguchi	Department of Pediatric Surgery, Reproductive and Developmental Medicine, Graduate School of Medical Sciences, Kyushu University
Takeshi Tomomasa	PAL Children’s Clinic
Masaki Nio	Department of Pediatric Surgery, Tohoku University Graduate School of Medicine
Hiroshi Tamai	Department of Pediatrics, Osaka Medical College
Masanori Tamura	Department of Pediatrics, Center for Maternal, Fetal and Neonatal Medicine, Saitama Medical Center, Saitama Medical University
Haruhiko Sago	Department of Perinatal Medicine and Maternal Care, National Center for Child Health and Development
Akira Toki	Division of Pediatric Surgery, Department of Surgery, Showa University School of Medicine
Shunsuke Nosaka	Department of Radiology, National Center for Child Health and Development
Tatsuo Kuroda	Department of (Pediatric) Surgery, Keio University School of Medicine
Masahiro Yoshida	Chemotherapy Research institute, KAKEN Hospital

2) Guideline development group

Hiroshi Matsufuji	Department of Pediatric Surgery, St Luke's International Hospital
Atsushi Nakajima	Department of Gastroenterology and Hepatology, Yokohama City University School of Medicine
Hiroyuki Kobayashi	Department of Hospital Administration, Juntendo University
Hideki Sou	Department of Pediatric Surgery, Osaka Women’s and Children’s Hospital
Kouji Masumoto	Departments of Pediatric Surgery, Faculty of Medicine, University of Tsukuba
Yoshio Watanabe	Department of Pediatric Surgery, Aichi Children's Health and Medical Center
Yutaka Kanamori	Division of Surgery, Department of Surgical Specialties, National Center for Child Health and Development
Yoshinori Hamada	Division of Pediatric Surgery, Department of Surgery, Kansai Medical

	University
Atsuyuki Yamataka	Department of Pediatric General and Urogenital Surgery, Juntendo University School of Medicine
Naoki Shimojima	Department of Surgery, Tokyo Metropolitan Children's Medical Center
Takeshi Tomomasa	PAL Children's Clinic
Akio Kubota	Second Department of Surgery, Wakayama Medical University
Kosuke Ushijima	Department of Pediatrics and Child Health, Kurume University School of Medicine
Ken Haruma	General Internal medicine 2, General Medical Center, Kawasaki Medical School
Shin Fukudo	Department of Behavioral Medicine, Tohoku University Graduate School of Medicine

3) Systematic review team

Yuko Araki	Department of Pediatric Surgery, St Luke's International Hospital
Takahiro Kudo	Department of Pediatrics, Juntendo University Faculty of Medicine
Satoshi Obata	Department of Pediatric Surgery, Reproductive and Developmental Medicine, Graduate School of Medical Sciences, Kyushu University
	Department of Advanced Medicine & Innovative Technique, Kyushu University Hospital
Wataru Sumida	Department of Pediatric Surgery, Aichi Children's Health and Medical Center
Toshihiko Watanabe	Division of Surgery, Department of Surgical Specialties, National Center for Child Health and Development
Suguru Fukahori	Department of Pediatric Surgery, Kurume University School of Medicine
Yoshimitsu Fujii	Division of Pediatrics, Tohoku Medical and Pharmaceutical University
Yoshiyuki Yamada	Division of Allergy and Immunology, Gunma Children's Medical Center
Keisuke Jimbo	Department of Pediatrics, Juntendo University Faculty of Medicine
Fujimi Kawai	St.Luke's International University Library
Tomoya Fukuoka	Department of Pediatric Gastroenterology, Nutrition and Endocrinology, Osaka Women's and Children's Hospital
Shinsuke Onuma	Department of Pediatric Gastroenterology, Nutrition and Endocrinology, Osaka Women's and Children's Hospital

4) External evaluation committee member

Toshio Morizane Chief Visiting Researcher, Japan Council for Quality Health Care

5) Administration office for the guideline development

Satoshi Ieiri Department of Pediatric Surgery, Kagoshima University

Genshiro Esumi	Department of Pediatric Surgery, Reproductive and Developmental Medicine, Graduate School of Medical Sciences, Kyushu University Perinatal Maternal Center, Kyushu University Hospital
Takahiro Jimbo	Department of Pediatric Surgery, Reproductive and Developmental Medicine, Graduate School of Medical Sciences, Kyushu University Department of Pediatric Surgery, Tsuchiura Kyodo General Hospital
Satoshi Obata	Department of Pediatric Surgery, Reproductive and Developmental Medicine, Graduate School of Medical Sciences, Kyushu University Department of Advanced Medicine & Innovative Technique, Kyushu University Hospital
Tomoko Yamasaki	Department of Pediatric Surgery, Reproductive and Developmental Medicine, Graduate School of Medical Sciences, Kyushu University

2. Development process

1) Policy

Allied disorders of Hirschsprung's disease consist of the following seven diseases: (1) immaturity of ganglia, (2) isolated hypoganglionosis, (3) intestinal neuronal dysplasia (IND), (4) megacystis-microcolon-intestinal hypoperistalsis syndrome (MMIHS), (5) segmental dilatation of intestine, (6) internal anal sphincter achalasia (IASA), and (7) chronic idiopathic intestinal pseudo-obstruction (CIIP). The guideline development committee members, as specialists in each disease, explained the basic characteristics of allied disorders of Hirschsprung's disease overall and described each disease in detail. Since the pathological diagnosis plays the most important role in determining the clinical practice policy for allied disorders of Hirschsprung's disease, a segment on pathological approach was created.

Four allied disorders of Hirschsprung's disease immaturity of ganglia, IND, segmental dilatation of intestine, and IASA show a good clinical course and are extremely rare; as such, these diseases are likely to rarely cause confusion when making therapeutic decisions in clinical practice.

Although the other three diseases isolated hypoganglionosis, MMIHS, and CIIP are also rare diseases, quite a few cases have been documented, and their clinical course is serious. These three diseases may therefore require the consideration of evidence and fair opinions from specialists when making decisions on their treatment in clinical practice. For these reasons, these three diseases were selected as targets of the clinical questions (CQs) of this guideline.

This guideline was developed using the methodologies in the "Minds Handbook for Clinical Practice Guideline Development 2014" and the "Minds Manual for Clinical Practice Guideline Development." However, as we expected difficulty in obtaining high-quality evidence on each disease, a unique approach was used for the systematic review. As the scope of the CQ includes intractable diseases, the

opinions from the guideline development committee members, as specialists, are extremely important. The committee members therefore held protracted discussions in order to prevent them from relying too heavily on their individual experiences, thereby helping them to build up a consensus.

2) Precautions

No clinical practice guideline for this group of diseases has yet been drafted. As many of the diseases in this group develop in childhood, clinical practice among pediatric patients was the focus in compiling this guideline. However, an increasing number of cases are enjoying a long-term survival due to recent progress in medicine; therefore, clinical practice for the transitional period from childhood to adulthood was also considered. Regarding clinical practice for CIIP that develops in adulthood, the “Clinical practice guideline for adults with chronic idiopathic intestinal pseudo-obstruction” (Research Project on Measures for Intractable Diseases, Health Labour Sciences Research Grant in 2011 fiscal year: Nakajima’s group) should be referenced.

3) Conflict of interest

There are no conflicts of interest to disclose among the stakeholders related to the development of this guideline.

4) Funding for the development

This guideline development was funded by the following research projects:

- “Nation-wide survey and Proposal of guideline in Hirschsprung’ disease allied disorders” (The Ministry of Health, Labour and Welfare of Japan, Health Labour Sciences Research Grant in fiscal year 2011: Tomoaki Taguchi’s group)
- “Comprehensive investigation and establishment of guideline in pediatric intractable hepato-gastrointestinal disease” (The Ministry of Health, Labour and Welfare of Japan, Health Labour Sciences Research Grant in fiscal years 2012-2013: Tomoaki Taguchi’s group)
- “Establishment of guideline including transition in pediatric intractable gastrointestinal disease” (The Ministry of Health, Labour and Welfare of Japan, Health Labour Sciences Research Grant in fiscal years 2014-2016: Tomoaki Taguchi’s group)

V. SCOPE

1. Basic characteristics of allied disorders of Hirschsprung's disease

1) *Clinical characteristics of allied disorders of Hirschsprung's disease*

a. Background

Hirschsprung's disease is characterized by a transit disorder of intestinal content, delayed meconium excretion, abdominal distention, bilious vomiting, constipation, and intestinal dilatation (megacolon) at the proximal side, resulting from dysperistalsis and a lack of a recto-anal reflex caused by aganglionosis of the intestinal tract at the distal side. In the field of pediatric surgery, this disease has been widely recognized, and the condition has been elucidated and appropriate therapy developed.

However, in this clinical and research setting, a group of diseases with similar symptoms and laboratory findings to Hirschsprung's disease despite the presence of ganglion cells in the rectum has also been recognized and is termed "allied disorders of Hirschsprung's disease" in Japan. The disease concept and diseases included in the group have changed over time, and a consensus has yet to be established among specialists.

A nationwide survey on the subject was conducted in the project of "Nation-wide survey and Proposal of guideline in Hirschsprung' disease allied disorders" (The Ministry of Health, Labour and Welfare of Japan, Health Labour Sciences Research Grant in fiscal year 2011: Tomoaki Taguchi's group). In the next project, "Comprehensive investigation and establishment of guideline in pediatric intractable hepato-gastrointestinal disease" (The Ministry of Health, Labour and Welfare of Japan, Health Labour Sciences Research Grant in fiscal years 2012-2013: Tomoaki Taguchi's group), specialists in pediatric surgery, pediatric gastrointestinal medicine, and adult gastrointestinal medicine determined the disease concept, classification, diagnostic criteria, and classification of severity. Subsequently, the development of a clinical guideline for allied disorders of Hirschsprung's disease was decided in the project of "Establishment of guideline including transition in pediatric intractable gastrointestinal disease" (The Ministry of Health, Labour and Welfare of Japan, Health Labour Sciences Research Grant in fiscal years 2014-2016: Tomoaki Taguchi's group).

b. Definition of allied disorders of Hirschsprung's diseases

Allied disorders of Hirschsprung's disease is a disease group characterized by symptoms and signs similar to those of Hirschsprung's disease, such as bowel obstruction, intestinal dilatation, and chronic constipation, despite the presence of ganglionic cells in the rectum.

c. Classification of allied disorders of Hirschsprung's disease

The following seven diseases below are defined as allied disorders of Hirschsprung's disease, and are classified based on the pathological findings of intestinal nerves from hematoxylin and eosin (HE) or acetylcholinesterase (AChE) staining of the intestinal tract or rectal mucosa samples collected at surgery or a biopsy.

-
- Diseases with abnormality in the intestinal ganglion cells
 - (1) Immaturity of ganglia
 - (2) Isolated hypoganglionosis
 - (3) Intestinal neuronal dysplasia (IND)
 - Diseases without abnormality in the intestinal ganglion cells (HE or AchE staining)
 - (4) Megacystis-microcolon-intestinal hypoperistalsis syndrome (MMIHS)
 - (5) Segmental dilatation of intestine
 - (6) Internal anal sphincter achalasia (IASA)
 - (7) Chronic idiopathic intestinal pseudo-obstruction (CIIP)
-

2) Epidemiological characteristics of allied disorders of Hirschsprung's disease

The table below shows the numbers of cases with allied Hirschsprung's diseases and the 10-year survival rates major pediatric medical institutions in Japan. Data were obtained in the project of "Nation-wide survey and Proposal of guideline in Hirschsprung's disease allied disorders" (The Ministry of Health, Labour and Welfare of Japan, Health Labour Sciences Research Grant in fiscal year 2011: Tomoaki Taguchi's group).

Allied disorders of Hirschsprung's disease	Number of cases for the primary survey	Number of cases for the secondary survey	Number of definitive cases	Survival rate
● Abnormal ganglion cell group				
(1) Immaturity of ganglia	19	28	28	100%
(2) Isolated hypoganglionosis	114	90	70	78%
(3) Intestinal neuronal dysplasia	17	11	11	100%
● Normal ganglion cell group				
(4) Megacystis-microcolon-intestinal hypoperistalsis syndrome	29	19	10	53%
(5) Segmental dilatation of intestine	35	28	27	96%
(6) Internal anal sphincter achalasia	6	2	2	100%
(7) Chronic idiopathic intestinal pseudo-obstruction	94	56	56	89%

3) Overall flow of clinical practice for each allied disorders of Hirschsprung's disease

Histopathology of allied disorders of Hirschsprung's disease

This disease group is not associated with aganglionosis, but its clinical symptoms and findings are similar to Hirschsprung's disease and include bowel obstructive symptoms such as abdominal distention, abdominal pain, bilious emesis, and dilatation of intestinal tracts; delayed meconium excretion; and constipation. For this reason, a histological evaluation plays an important role in the diagnosis of allied disorders of Hirschsprung's disease. The histological evaluation of enteric ganglions, especially in neonates and infants, requires professional knowledge and experience.

The majority of neonatal ileus cases may result in emergent laparotomy, and some diseases in this group requiring a histological evaluation (isolated hypoganglionosis, immaturity of ganglia) must be distinguished from small bowel atresia and Hirschsprung's disease (aganglionosis).

Ideally, intestinal full-thickness biopsy samples should be collected at the three points indicated in

the flow chart (**Figure 1**), with HE staining and immunohistological investigations used for the histopathological diagnosis (**Figures 2–4**). Anti-HuC/D antibody has excellent sensitivity and specificity for identifying immature and small neurocytes of neonates and infants. Sox10 antibody positivity in intestinal glia cell nuclei is useful for differentiating immature neurocytes from intestinal glia cells. When the neural plexus is normal in size and ganglion cells are normal in number and size in samples obtained by full-thickness biopsies from the stoma site at the oral side sufficiently far from the caliber change and from the terminal ileum, Hirschsprung's disease should be diagnosed if hypertrophic acetylcholinesterase-positive nerve fibers in the lamina propria mucosae is observed in samples obtained by a rectal mucosal biopsy or if a lack of myenteric ganglion cells and nerve fascicle formations is observed in a sample obtained by a full-thickness biopsy from the sigmoid colon.

A useful indicator for the diagnosis of isolated hypoganglionosis is the presence of ≤ 20 HuC/D-positive cells per centimeter within the muscularis propria in a specimen from a resected intestinal tract, as this is a significantly lower number than that noted in normal intestinal tract.

For the diagnosis of immaturity of ganglia with immature neurocytes but no abnormal numbers, present in normal sized nerve plexus, the final diagnosis should be made based on the absence of any abnormality in the nerve plexus and neurocytes at the time of stoma closure.

Figure 1. Histopathological differentiation of allied disorders of Hirschsprung's disease

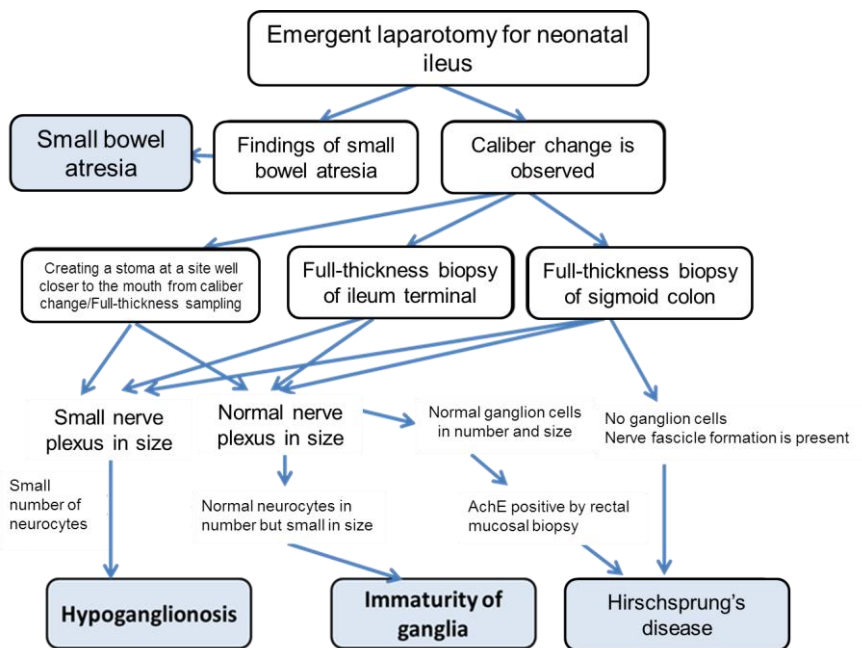


Figure 2. Normal Auerbach's myenteric plexus

Several matured ganglion cells are observed in the nerve plexus.

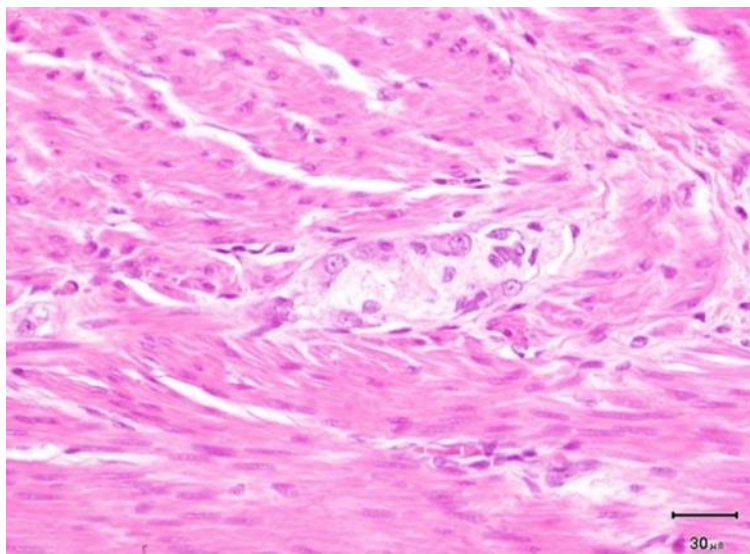


Figure 3. Immaturity of ganglia, Auerbach's myenteric plexus

The nerve plexus is normal in size, and ganglion cells are normal in number but small and immature.

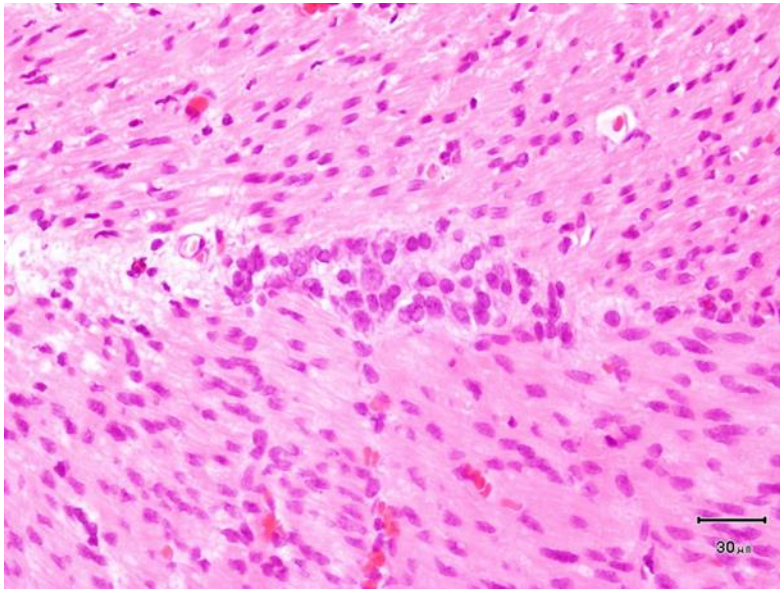
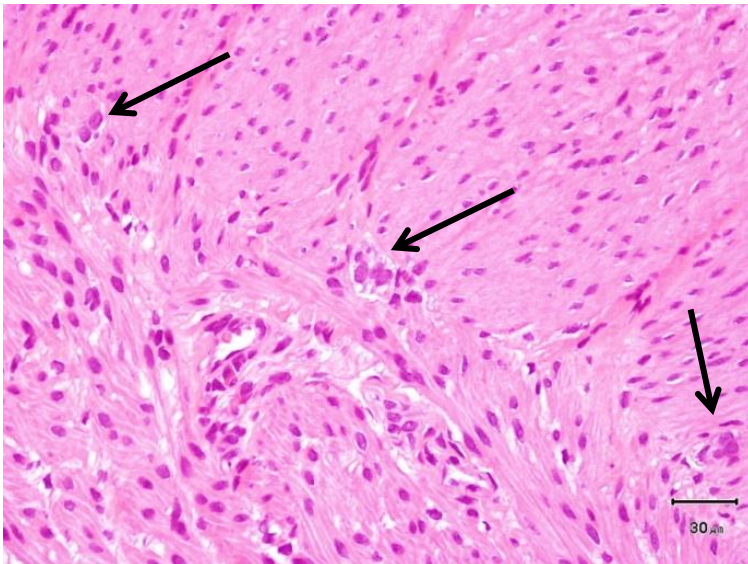


Figure 4. Isolated hypoganglionosis, Auerbach's myenteric plexus (arrow)

The nerve plexus is small and, the number of ganglion cells is decreased.



(1) Immaturity of ganglia

Disease concept: Neonatal ileus symptoms present with a clinical manifestation similar to meconium disease. In a barium enema examination, narrowing of the colon is observed (microcolon or small colon). In the neonatal period, the recto-anal reflex is negative in many cases, but turns positive in infancy. A rectal mucosal biopsy can differentiate immaturity of ganglia from Hirschsprung's disease based on the lack of hypertrophic AchE-positive nerve fibers. As the lesion may extend to the small bowel, ileostomy is required in many cases during the neonatal period. On a pathological examination, the intramural ganglion cells are sufficient in number but are small and markedly immature. Neurocytes may mature in several months, and ileostomy closure can be performed. Both the vital and functional prognoses of this disease are good.

Diagnostic criteria

Primary diagnostic criteria

- 1) Develops during the neonatal period
- 2) Affected bowel may extend to the small bowel
- 3) Caliber change is observed during surgery

Secondary diagnostic criteria

- 1) Symptoms improve over time
- 2) On diagnostic imaging, microcolon or narrowing of the left hemicolon is present.

Pathological diagnostic criteria (1 and 2 or 1 and 3 need to be met)

- 1) Immature ganglion cells (small in size)
- 2) Normal number and distribution of ganglion cells
- 3) Ganglion cells mature over time

Isolated hypoganglionosis is diagnosed based on an indispensable pathological examination at enterostomy if two or more primary diagnostic criteria, or if one primary plus two secondary diagnostic criteria are met.

A nationwide survey followed 28 cases for 10 years from 2001 to 2010. The number of cases with definitive diagnoses meeting the above criteria (proposed) was 15, and all of them survived.

(2) Isolated hypoganglionosis

Disease concept: Isolated hypoganglionosis is a disease that causes serious functional bowel obstruction during the neonatal period or later, and is a congenital gastrointestinal disease with poor prognosis. In English, it is expressed as 'isolated hypoganglionosis' in order to distinguish it from the site with reduced neurocytes (transitional zone) observed between the aganglionic and normoganglionic segment in Hirschsprung's disease.

Most cases require stoma (enterostomy) and parenteral nutrition for life support over a long period of time, and severe cases are potential candidates for small bowel transplantation. It is difficult to differentiate isolated hypoganglionosis from Hirschsprung's disease by a barium enema examination or anorectal manometry.

An intestinal pathological examination shows that the intestinal nerve plexus is small with few ganglion cells. In this respect, it is difficult to differentiate the isolated hypoganglionic tract from the transition zone of Hirschsprung's disease between the aganglionic and normoganglionic tract. The individual ganglion cells in the whole intestinal tract are small in size during the neonatal period, but they grow over time as they mature, although their number will never increase. Isolated hypoganglionosis can be distinguished from Hirschsprung's disease in that it has no exogenous nerve fiber growth in the colon and no nerve fiber growth at the distal colon. Laparotomy is required to resolve bowel obstruction during the neonatal period. A definitive diagnosis can be made by a pathological examination with a full-thickness intestinal biopsy.

Diagnosis criteria

- 1) Bowel obstruction symptoms present in the early neonatal period
- 2) The intestinal nerve plexus is hypoplastic and the number of ganglion cells is significantly smaller than normal on a pathological examination

Note) In the neonatal period, Hirschsprung's disease can be ruled out using frozen section of full-thickness intestinal specimens collected from the jejunum or ileum (both if possible) and sigmoid colon. At the second laparotomy, at two months of age or later, such as when changing a double-barrel fistula into a Bishop-Koop type fistula, permanent preparations of the entire intestinal circumference should be created to assess the decrease in ganglionic cell number.

Severity criteria

A severe case is defined as one whose daily life is significantly impaired due to bowel obstruction symptoms, such as abdominal distension, nausea and vomiting, and abdominal pain, and when at least one of the following three items is met:

- 1) Parenteral nutrition is required.
- 2) Enteral nutrition is required.

3) Continuous gastrointestinal decompression is required.^{Note)}

Note) Gastrointestinal decompression refers to the drainage of intestinal contents through enterostomy, gastrostomy, nasogastric tube, ileus tube, transanal tube, etc.

Basic clinical practice policy is to provide adequate nutrition via central venous parenteral nutrition and/or enteral nutrition and to perform appropriate decompression surgery in order to prevent congestive enteritis. Decompression necessarily requires enterostomy. The enterostomy site is important, as the first stoma site is a key factor in determining the treatment outcome of isolated hypoganglionosis. In the nationwide survey conducted in 2001-2010, cases that underwent jejunostomy at the first surgery had better outcomes than those with ileostomy. Regarding the appropriateness of resection of the functionally disordered intestinal tract at the anal side from enterostomy, the need for preservation may be suggested based on the outcome of the experimental treatments. Unfortunately, however, no cohort study has yet been conducted, so further studies are needed before any conclusions can be made. Severe cases can also be saved by organ transplantation, and future studies should examine the appropriateness of small bowel transplantation versus multiorgan transplantation for such patients.

(3) Intestinal Neuronal Dysplasia (IND)

Disease concept: IND was first described by Meier-Ruge in 1971, which he further classified into two types: Type A and Type B. Type A is very rare, accounting for about 5% of all IND cases, and is associated with bowel obstruction, diarrhea, and bloody stool during the neonatal period. Reduced innervation of the intestinal sympathetic nervous system is also typically observed.

As Type B can account for up to 95% of IND cases, this section will focus on Type B IND. In IND Type B, blockage of the lower gastrointestinal tract similar to that of Hirschsprung's disease is observed. A barium enema examination does not provide any characteristic findings of IND except for dilation of the rectosigmoid colon. Recto anal reflex examinations display both positive and negative cases of IND. In terms of pathology, malformation of the intestinal parasympathetic nervous system is present in patients with IND. AchE staining, displays evidence of submucosal giant ganglia, hyperganglionosis, ectopic ganglia, and the growth of AchE-positive nerve fibers (**Figure 5**). These conditions may exist independently, with anal atresia, or with intestinal segments consisting of normal ganglion cells in Hirschsprung's disease. Whether these pathological findings are due to congenial change, secondary change related to growth and development, or due to constipation remains controversial. Conservative therapies, such as laxatives or use of an enema, can often control conditions related to IND. If these conditions cannot be improved through conservative methods, resection of the internal anal sphincter is advised. Intestinal resection may also be required in rare cases. Reports of morbidity rates across institutions tend to differ due to lack of common diagnostic criteria and pathological investigation strategies. In order to address this issue, uniform diagnostic criteria and practiced methodologies are essential and must be shared among institutions.

Diagnostic criteria

The following three items must be met:

- 1) Symptoms similar to Hirschsprung's disease
- 2) Presence of both
 - a) Giant ganglia (≥ 9 ganglion cells in one ganglia)
 - b) Growth of AchE-positive nerve fibers
- 3) Neonates and infants are not applicable

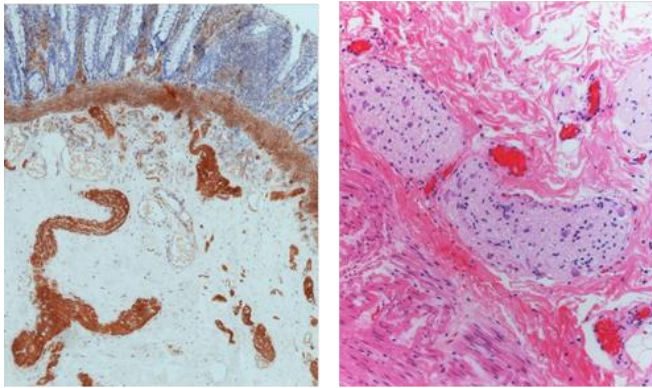
Note) Neonatal and infant cases that meet criteria 1) and 2) need to be strictly monitored as potential IND cases.

In a nationwide survey conducted over a 10 year period, from 2001 to 2010, 8 definitive and 9 suspected cases were enrolled, with 11 cases confirmed as IND. The most common onset time was the neonatal and infancy period, followed by childhood. There have only been a few reports of IND cases in Japan, while some cases may have been diagnosed under chronic functional constipation.

Figure 5. Intestinal Neuronal Dysplasia (IND)

Acetylcholinesterase staining (left): Submucosal giant ganglia is observed.

HE staining (right): Many ganglion cells are observed in a large nerve plexus.



(4) Megacystis-microcolon-intestinal hypoperistalsis syndrome (MMIHS)

Disease concept: A serious disease that presents as bowel obstruction-like symptoms in the neonatal period and later, resulting in intestinal failure, which is accompanied by megacystis and microcolon. Many such cases require gastrointestinal decompression via gastrostomy or intestinal stoma during neonatal period. In a pathological examination, no abnormality is observed in the intestinal nerve plexus.

Diagnostic criteria

- 1) Bowel obstruction symptoms such as abdominal distension, vomiting, and abdominal pain present immediately after birth
 - 2) Megacystis present
 - 3) Barium enema reveals microcolon in the neonatal period (Figure 6)
 - 4) No mechanical obstructive lesion observed in the gastrointestinal tract
 - 5) No pathological abnormalities observed in the neural plexus of a full-thickness intestinal biopsy specimen
-

Severity criteria

A severe case is defined as one whose daily life is significantly impaired due to bowel obstructive symptoms, such as abdominal distension, nausea, vomiting, and abdominal pain, and when at least one of the following three items is met:

- 1) Parenteral nutrition is required
- 2) Enteral nutrition is required
- 3) Continuous gastrointestinal decompression is required ^{Note)}

Note) Gastrointestinal decompression refers to the drainage of intestinal contents through enterostomy, gastrostomy, nasogastric tube, ileus tube, transanal tube, etc.

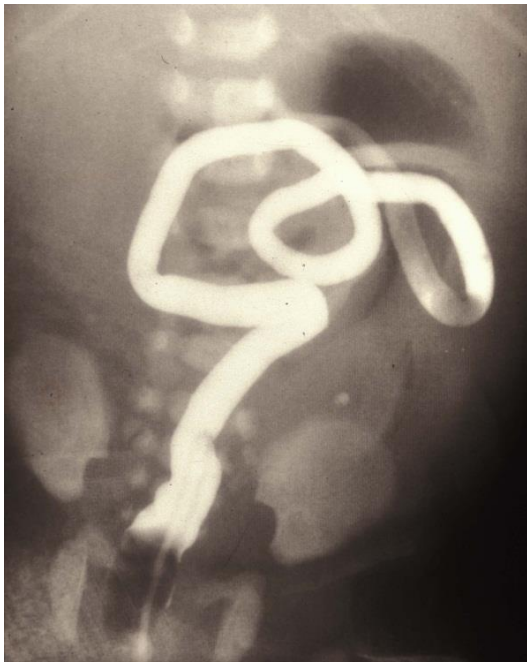A nationwide survey conducted over 10 years from 2001 to 2010 enrolled 19 definitive and 5 suspected cases. Enterostomy was performed for 16 out of the 19 definitive cases for decompression.

Due to intestinal failure, parenteral nutrition or enteral nutrition needs to be used for a long period of time. Four out of the 19 cases needed total parenteral nutrition, and 12 needed concomitant use of parenteral nutrition and enteral nutrition. Seven out of the 9 surviving cases required parenteral nutrition. For this reason, serious complications, such as hepatic disorder, catheter-related bloodstream infection, enteritis, and bacterial translocation, can easily occur with this disease.

Ten out of the 19 cases survived, and 9 cases died, with a 5-year survival rate of 62.8% and 10-year rate of 56.5%. The main causes of death were hepatic disorder and sepsis.

Figure 6 Barium enema image of MMIHS

Microcolon is observed.



(5) Segmental Dilatation of Intestine

Disease concept: Segmental dilatation of the intestine is a rare disease that presents with localized dilatation of intestines without mechanical bowel obstruction and malformation of the intestinal nerve plexus. Since Swenson and Rathauer reported this disease as a "new entity" in 1959, various causes have been discussed; however, the clinical manifestation and pathological findings vary, and the disease concept has never been determined in a simple manner. It may therefore be appropriate to regard it as a group of diseases that presents with localized intestinal dilatation.

Diagnostic criteria

This disease is diagnosed when the following six items are met:

- 1) Intestinal tract segmentally (permanently) dilated
 - 2) Normal intestinal segment abruptly transitions to a dilated segment
 - 3) No endogenous or exogenous cause of obstruction noted at the anal side of the dilated segment
 - 4) Complete or partial bowel obstruction observed on diagnostic imaging
 - 5) Normal distribution of the nerve plexus on a pathological examination
 - 6) Resection of the lesion improves symptoms
-

Severity classification: If this disease is not complicated by any other diseases, resection of the lesion significantly improves the symptoms. The prognosis is good, and severity classification may be unnecessary.

Clinical manifestation: In Japan, although about 50 cases have been reported in the literature, no large-scale survey has been conducted in the past. A nationwide survey conducted over 10 years from 2001 to 2010 identified 37 cases, including 26 definitive and 9 suspected cases. Based on a secondary survey of these cases, 28 were determined as definitive cases by adding 2 of the suspected cases, after discussions at investigation group meetings and general meetings.

Gender: Regarding the 28 cases, 19 (68%) were boys and 9 (32%) were girls. Boys were more likely to present with this disease than girls.

Gestational week and birth weight: The gestational week was 30.2 weeks on average, with 7 cases (25%) of preterm deliveries. The average birth weight was 2,319 g. The number of low-birth-weight infants was 9 (32%), including 1 very-low-birth-weight infant and 2 extremely-low-birth-weight infants.

Chromosome aberration: Two cases (7.1%) of trisomy 21 was observed.

Family history: The majority (26 cases) had no family history, while 2 had a history. In one case, four cousins on the mother's side had segmental dilatation of the colon, and one of them died. The other case showed marked constipation.

Combined malformation: Seen in 7 cases out of 28 cases. Two cases had patent ductus arteriosus (PDA), and the remaining five cases had the following malformations (one each): Fallot's tetralogy, ventricular septal defect (VSD), cerebral palsy/colpocephaly/mandibular hypoplasia/low-set ears, FG syndrome,

Fallot's tetralogy/encephalatrophy/scoliosis/cleft lip and palate/low-set ears/horseshoe kidney/right hydronephrosis/hypospadias.

Gastrointestinal tract complications: Four out of 28 cases had complications, including 2 cases (7.1%) of malrotation, 1 case (3.5%) of ileal atresia, and 1 case (3.5%) of anal atresia.

Dilatation sites: Ileum was the most common (14 cases, 50%) site, followed by sigmoid colon (5 cases, 18%), jejunum (3 cases, 11%), transverse colon (3 cases, 11%), from the cecum to transverse colon (1 case), cecum (1 case), and duodenum (1 case).

Onset time: The neonatal period (18 cases, 64%) was the most common, and with the frequency decreasing with increasing age as follows: infancy (6 cases, 21%), childhood (2 cases, 7.1%), and school age or later (2 cases, 7.1%).

Initial symptom: Abdominal distension (20 cases, 71%), vomiting (13 cases, 46%), abnormality noted on a prenatal diagnosis (7 cases, 25%), chronic constipation (6 cases, 21%), and delayed meconium excretion (4 cases, 14%). One case had strangulated ileus due to midgut volvulus, and another had intestinal perforation.

Examination findings: Twenty-five cases (89%) showed abnormal dilatation of the intestine on plain abdominal X-ray. A barium enema examination was performed for 23 cases, of which 12 (52%) were diagnosed with segmental dilatation of intestine. Seven cases (25%) were found to have intestinal dilatation by ultrasonography or magnetic resonance imaging (MRI) in the prenatal period. The rectoanal reflex was positive in all seven examined cases, and no increase in acetylcholinesterase-positive nerve fibers was seen in any of the five cases in which a rectal mucosal biopsy were performed.

Diagnosis: Plain abdominal radiography successfully indicated the presence of the lesion in many cases (**Figure 7**). A preoperative diagnosis also requires confirmation of the segmental intestinal dilatation by contrast radiography or computerized tomography (CT). When the dilatation site is in the colon, it needs to be differentiated from Hirschsprung's disease. A caliber change should be observed clearly at the oral side of the dilated segment by barium enema for this disease. If it is not clear, anorectal manometry or a rectal mucosal biopsy is required for the differentiation.

Treatment: Resection of the dilated segment (**Figure 8**) and end-to-end anastomosis of the intestine will provide a good prognosis. Surgery was performed in 27 cases, and 1 case was waiting for surgery. Laparotomy was performed for the resection of the dilated segment and intestinal anastomosis in 26 cases out of 27 cases. For 1 case, segmental dilatation of intestine (SD) was detected during the surgery for malrotation, and the patient was followed up without resection. However, the dilatation persisted, and it was resected after the survey. Out of the 26 cases in which resection of dilated segment and intestinal anastomosis were performed, enterostomy was created in 4 cases, and gastrostomy was created in 2 cases. Surgery was performed during the neonatal period in 13 cases (48%), infancy in 4 cases (15%), childhood in 5 cases (19%), and school-age in 3 cases (11%).

Prognosis: A total of 27 cases are surviving with a good prognosis. One patient died: a 9-year-old boy with cerebral palsy who had segmental dilatation in the cecum. Ileocecal resection was performed, but he died

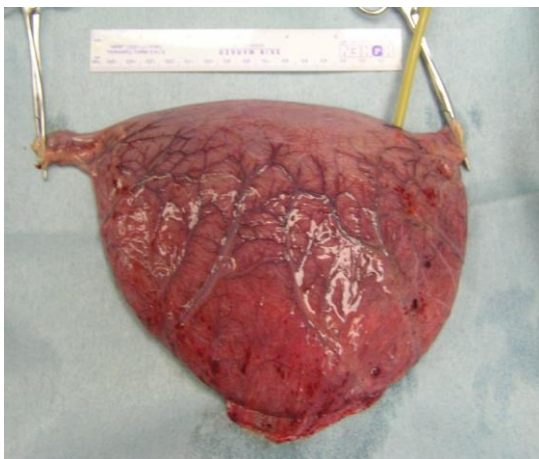
of sepsis, hepatic disorder, and catheter infection at 12 years of age. A necrotic change was observed in a resected specimen.

Figure 7. Plain abdominal X ray of segmental dilatation of intestine

Seven months of age. Marked intestinal dilatation and air-fluid level are observed.

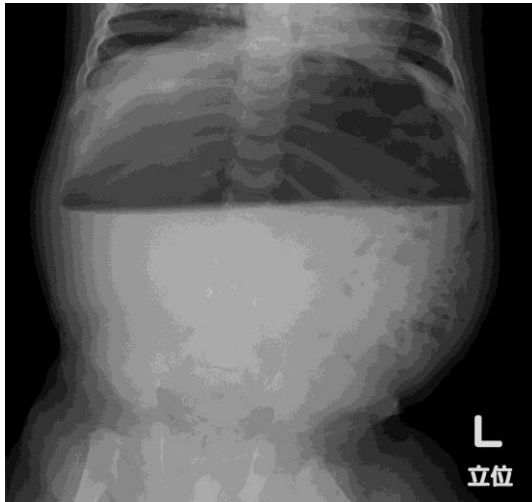

Figure 8. Resected dilated intestinal segment



(6) Internal Anal Sphincter Achalasia (IASA)

Disease concept: IASA is a disease that shows intractable constipation due to relaxation failure of the internal anal sphincter despite the presence of ganglion cells in the rectal wall.

This disease has been reported to account for 4.5% of chronic constipation in childhood and may be incorrectly diagnosed as chronic functional constipation. Regarding the treatment, in addition to medication, resection of the internal anal sphincter and botulinum toxin injection are performed. The prognosis of this disease is very good.

Diagnostic criteria

- 1) Refractory constipation present
- 2) No narrowing of the rectum observed under contrast enema
- 3) Negative recto anal reflex
- 4) Ganglion cells present in the specimen from a rectal mucosal biopsy

(Notes on diagnosis)

- The recto anal reflex should be evaluated with definite stimulation of the rectum after emptying the rectal contents, and the absence of a relaxation response of the internal anal sphincter should be confirmed.
 - The status of AchE-positive nerve fibers should be checked when possible.
-

A total of 6 cases, including 3 cases in the primary nationwide survey conducted over 10 years from 2001 to 2010 and an additional 3 cases, were enrolled, and 2 met the above diagnostic criteria.

(7) Chronic Idiopathic Intestinal Pseudo-obstruction (CIIP)

Disease concept: CIIP is an intractable disease with unknown etiology that presents with prolonged bowel obstructive symptoms, such as abdominal distension, nausea and vomiting, and abdominal pain. Dilated bowel and air-fluid levels are shown on radiological examinations.

Chronic intestinal pseudo-obstruction (CIPO) is defined as functional motility disorder, presenting obstructive symptoms without mechanical obstruction to prevent the transportation of the gastrointestinal contents. CIPO is classified into three types: primary type, caused by gastrointestinal lesions; secondary type, associated with systemic illness or drugs; and idiopathic type with unknown etiology.

As the primary type includes Hirschsprung's disease (aganglionosis) and allied disorders of Hirschsprung's disease (except CIIP), a diagnosis of childhood CIIP requires differentiation from these diseases. In the diagnosis of adult CIIP, it is important to differentiate secondary CIPO. In the adult domain, this disease remains recognized not only among general clinicians but even by medical practitioners specializing in the gastrointestinal tract. Inappropriate clinical practices and unrequired surgeries for the bowel obstructive conditions have been performed. Under these circumstances, "Clinical practice guideline for chronic intestinal pseudo-obstruction" (Research Project on Measures for Intractable Diseases, Health Labour Sciences Research Grant in fiscal year 2011: Nakajima's group) was released publicly. In contrast, in the child domain, there are many neonatal-onset cases, and the disease is recognized as an allied disorder of Hirschsprung's disease. This chapter mainly describes CIIP that develops in childhood.

Definition: CIIP is an intractable disease with unknown etiology, that presents with bowel obstructive symptoms, such as abdominal distension, nausea and vomiting, abdominal pain, and intestinal dilatation, due to gastrointestinal motility disorder despite the absence of anatomical obstruction.

Diagnostic criteria

The following 7 items need to be satisfied:

- 1) Persistent or repetitive development, over a long period of time, of symptoms of serious bowel obstruction that may require hospitalization, such as abdominal distension, nausea and vomiting, abdominal pain, etc.
- 2) Duration of symptoms is ≥ 2 months for neonatal onset and ≥ 6 months for onset in infancy or later
- 3) Gastrointestinal dilatation and air-fluid level noted on diagnostic imaging^{Note 1)}
- 4) No lesions mechanically blocking the gastrointestinal tract
- 5) No pathological abnormalities in the nerve plexuses on HE stained full-thickness intestinal biopsy specimens^{Note 2)}
- 6) Megacystis-microcolon-intestinal hypoperistalsis syndrome and segmental dilatation of intestine are excluded
- 7) Secondary chronic intestinal pseudo-obstruction is excluded.^{Note 3)}

Note 1) Confirmation of the air-fluid level on plain abdominal radiography in a standing position is not necessarily required for neonates.

Note 2) For adults, when an intestinal full-thickness biopsy is unobtainable, a characteristic peristalsis disorder should be confirmed by manometry or cine MRI.

Note 3) **Table 1** shows the secondary chronic intestinal pseudo-obstructions to be excluded.

Severity criteria

Severe case is defined as one whose daily life is significantly impaired due to bowel obstructive symptoms, such as abdominal distension, nausea and vomiting, and abdominal pain, and when at least one of the following three items is met:

1) Parenteral nutrition is required.

2) Enteral nutrition is required.

3) Continuous gastrointestinal decompression is required.^{Note)}

Note) Gastrointestinal decompression refers to the drainage of intestinal contents through enterostomy, gastrostomy, nasogastric tube, ileus tube, transanal tube, etc.

Table 1. Secondary chronic intestinal pseudo-obstruction

1) Gastrointestinal smooth muscle-related diseases

Systemic sclerosis

Dermatomyositis

Multiple myositis

Systemic lupus erythematosus

Mixed connective tissue disease (MCTD)

Ehlers-Danlos syndrome

Muscular dystrophy

Amyloidosis

Small bowel-based lymphoid infiltration

Brown bowel syndrome (Ceroidosis)

Mitochondrial encephalomyopathy

2) Gastrointestinal nerves-related diseases

Familial dysautonomia

Primary dysautonomia

Diabetic neuropathy

Myotonic dystrophy

Pseudo-obstruction after infection, such as EB virus, Herpes Zoster virus, and Rota virus

3) Endocrine diseases

Hypothyroidism

Hypoparathyroidism

Phaeochromocytoma

4) Metabolic diseases

Uremia

Porphyria

Serious electrolytes abnormality (K⁺, Ca²⁺, Mg²⁺)

5) Others

Celiac disease

Kawasaki disease

Eosinophilic enteritis

Paraneoplastic pseudo-obstruction

Mesenteric vein thrombosis

Side reactions to radiotherapy

Angioedema

Intestinal tuberculosis

Crohn's disease

Chagas disease

Paralytic ileus resulting from injury, after gastrointestinal surgery, intraperitoneal inflammation, etc.

Ogilvie syndrome

6) Drug-induced diseases

Antidepressant

Antianxiety drug

Anthraquinone-based laxative

Phenothiazine drugs

Vinca alkaloid

Anticholinergic drug

Opioid

Ca channel blocker

Verapamil

Clinical manifestation: In a nationwide survey conducted over 10 years from 2001 to 2010, the number of primary enrollments of childhood-onset CIPO was 92, of which 90% or more were idiopathic. Among these, 56 cases met the diagnostic criteria of CIIP. This disease may sporadically develop, and peristalsis disorders may occur at any sites or multiple sites of the gastrointestinal tract. Lesion sites (dilated intestines) are frequently observed in the small bowel and the colon (**Figures 9, 10**).

Symptoms: The major initial symptoms are abdominal distension and vomiting for neonatal and infant-onset cases, and abdominal distension, vomiting, constipation, and diarrhea for older children. Adult cases may often present with abdominal pain. In some cases suffering from long-lasting pseudo-obstructive symptoms, gastrointestinal resting may relieve the symptoms. However, in the majority of cases, remission and exacerbation may be repeated with progressing conditions.

Flow of clinical practices: CIIP is likely to develop in the neonatal period or infancy, with bowel obstructive symptoms requiring emergent operations for the diagnosis and treatment; older children may often show gradual progress of their condition. Neonatal and infant-onset cases require differentiation from Hirschsprung's disease, isolated hypoganglionosis, megacystis-microcolon-intestinal hypoperistalsis syndrome (MMIHS), and segmental dilatation of intestine. For this reason, an intestinal full-thickness biopsy on laparotomy and gastrointestinal decompression with enterostomy are attempted early after the onset in most cases.

For cases with an onset in older childhood and adulthood, when an intestinal full-thickness biopsy is

unobtainable, alternatively, a characteristic peristalsis disorder is checked for by cine MRI or manometry (Figures 11, 12). It is also important to differentiate the disease from mechanical bowel obstruction and secondary intestinal pseudo-obstruction (Table 1). We herein report the diagnostic diagrams for child and adult CIIP (Figures 13, 14).

Many cases progress gradually, with repeating remission and exacerbation. Treatment may start with conservative treatments, such as drug therapy and intravenous/enteral nutrition, and then shift to invasive treatments, such as decompression by tubing or enterostomy, as the condition progresses. Intestinal perforation, necrosis, and severe enteritis indicate surgical treatments. Even after enterostomy and resection of dilated segments, obstructive symptoms may relapse due to dysfunction in the remaining intestines in many cases. Thus, multiple surgeries, such as exploratory laparotomy, enterostomy, intestinal resection, and enterostomy closure may be performed in some cases. In a few cases, small bowel transplantation may be performed when these conservative treatments become ineffective due to complications or when patients have suffered from intolerable pain for a long period of time (Figure 15).

Prognosis: Although the prognosis is relatively good, repeated long-term hospitalization is needed. Even for outpatient cases, intravenous/enteral nutrition support, and enterostomy managements may significantly limit their daily life. When gastrointestinal decompression is not effective, intestinal perforation or enteritis may lead to sepsis, resulting in death.

A total of 53 (94.2%) out of 56 cases that met the diagnostic criteria are surviving for a long-term, but just a small part of them improved their conditions. The average duration of symptoms is 14.6 years, and the number of cases transitioning to adulthood CIIP is increasing. Nearly half of cases need gastrointestinal decompression via gastrostomy, enterostomy, or tubing. Furthermore, 74% of cases need some nutritional support, such as parenteral nutrition and/or enteral nutrition.

Figure 9 Plain abdominal X-ray of neonatal-onset CIIP

At day 8 after birth (left) and 4 months of age (right), intestinal dilatation is observed. No air-fluid levels are observed due to imaging in the prone position.

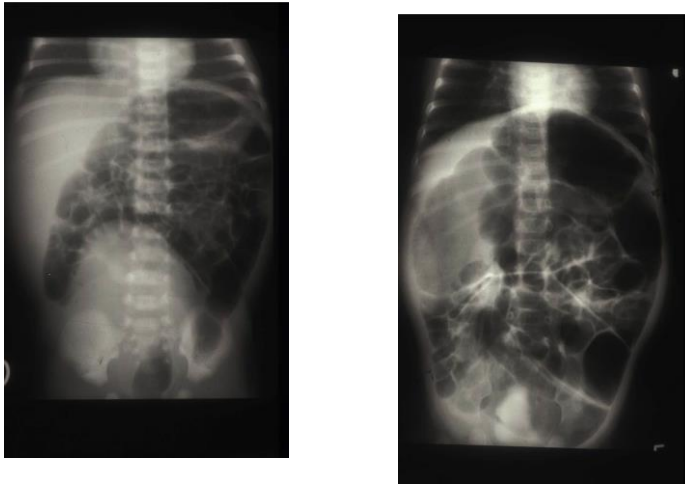

Figure 10 Plain abdominal X-ray of older childhood-onset CIIP

At 7 years of age (left), intestinal dilatation and air-fluid levels were present. At 17 years of age (right), the dilatation had progressed, and free air was observed under the diaphragm.

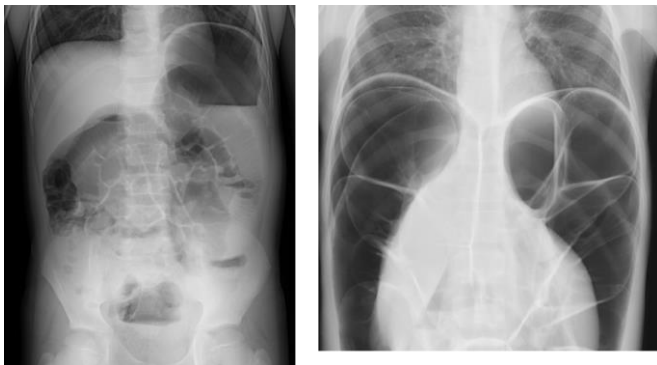
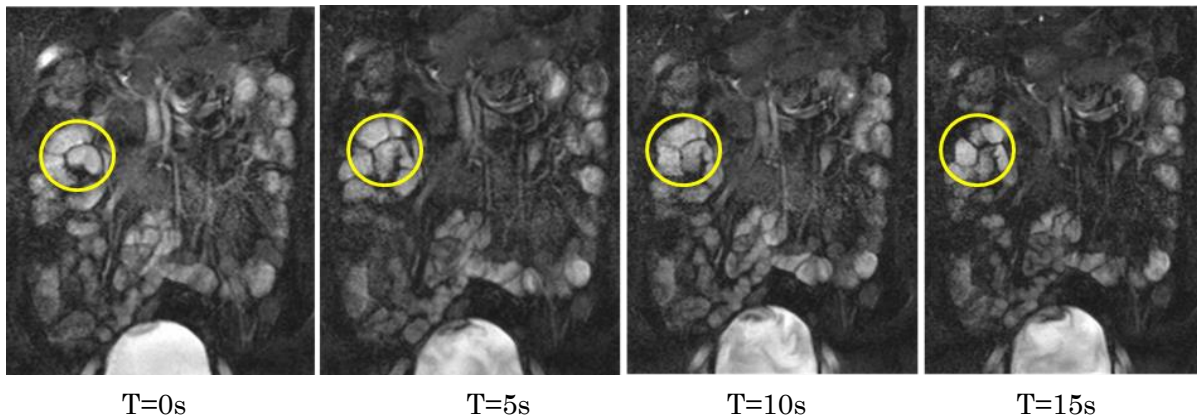
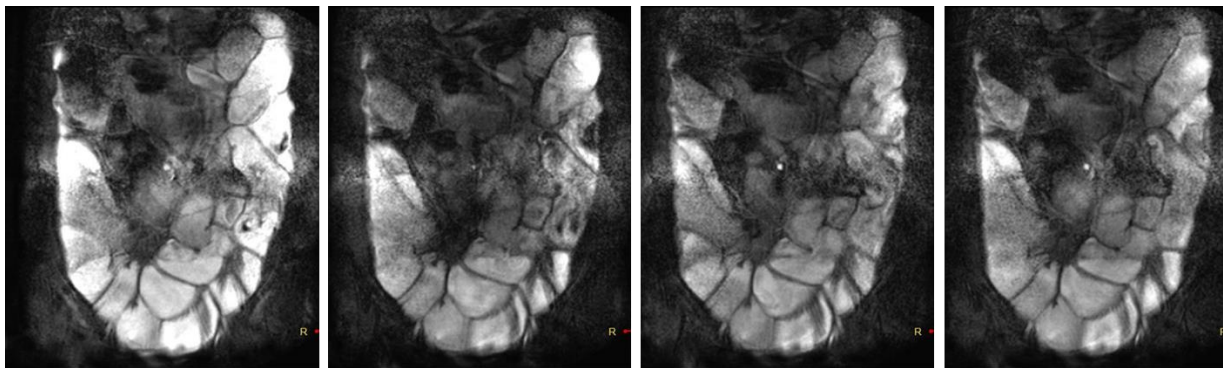


Figure 11. Cine MRI of chronic idiopathic intestinal pseudo-obstruction

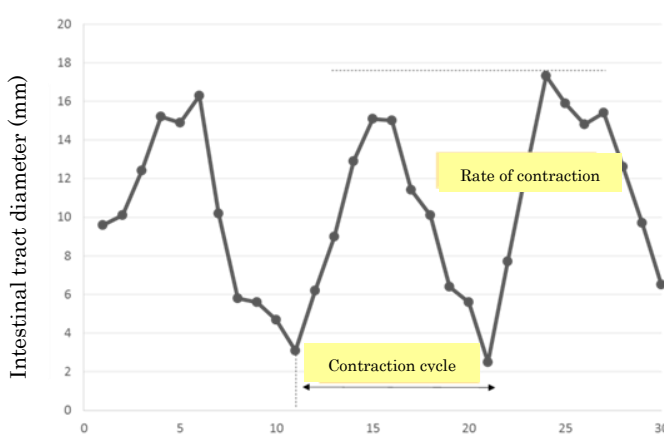
Peristalsis is evaluated by continuously regenerating 30 images obtained by about 15-second continuous shooting of the organ. Selecting a specific site (circle) to graphically show the temporal change in the diameter of the intestine is useful for a peristaltic evaluation. In healthy subjects, the diameter of the intestinal tract changes over time, with repeated contractions observed (a, c). In CIIP patients, the diameter of the intestinal tract hardly changes over time, and contractions are not noted (b, d).



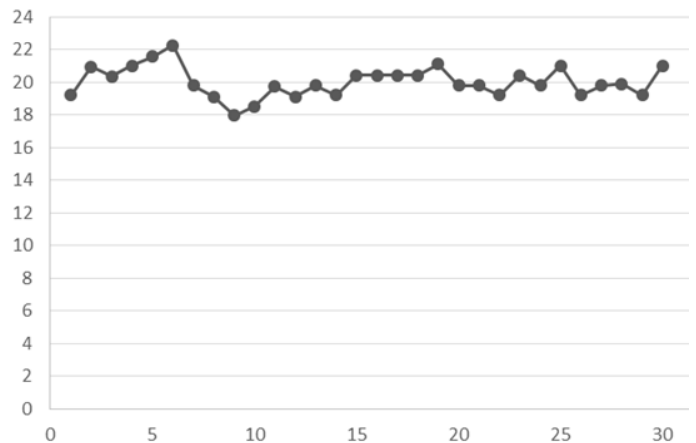
a) Healthy subject: No morbid dilatation of the small bowel is observed, and active intestinal peristalsis is maintained.



b) CIIP patient: Morbid dilatation of the small bowel is present with a marked decrease in peristalsis.



c) Healthy cases



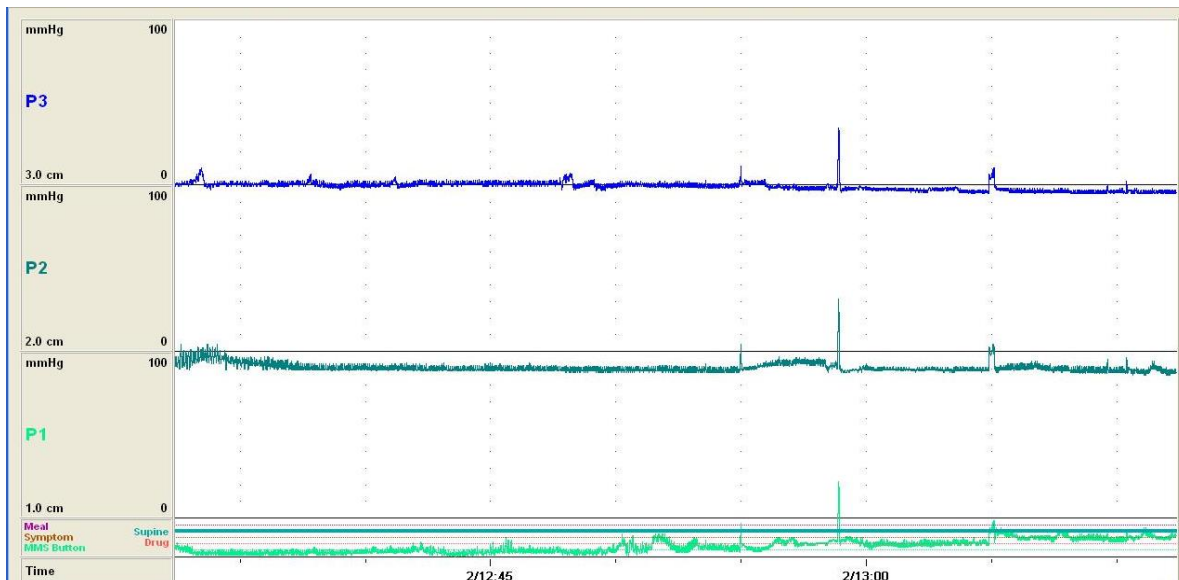
d) CIIP cases

Figure 12. Small bowel manometry for chronic idiopathic intestinal pseudo-obstruction

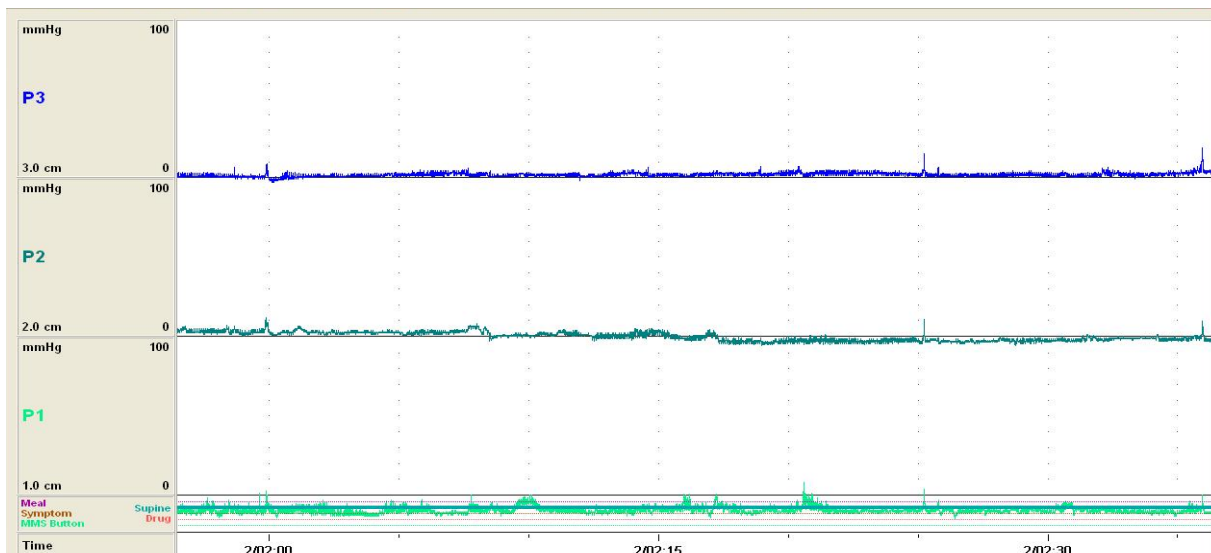
For the accurate evaluation of CIIP, an investigation of the abnormality in the small bowel motility is important. After inserting a pressure transducer catheter nasally into the small bowel, the motility is measured over 24 h.

Upper: Oral side, Middle: Anal side by 5 cm, Lower: Anal side by 10 cm. Horizontal axis: Time (5-minute interval scale), Vertical axis: Pressure (mmHg).

In healthy subjects, the interdigestive small bowel motility and postprandial small bowel motility can be easily distinguished. Interdigestive small bowel motility consists of phase I with no contractions, phase II with irregular contractions, and phase III in which 11 to 12 tetanic contractions per minute, and these phases in this order are repeated periodically. Postprandial small bowel motility is induced with eating and is characterized by irregular contractions. The absence of a normal small bowel motility pattern was confirmed during the daytime with a CIIP patient shown below (a). Nighttime is suitable for evaluating the interdigestive small bowel motility, as the interdigestive time is longest between dinner and breakfast for the typical person, and agitation of the central nervous system may not easily influence the gastrointestinal tract. Normally, the characteristic phase III that occurs periodically is observed during the nighttime. However, phase III was not noted, and the absence of a normal small bowel motility pattern was confirmed while sleeping at night in the CIIP patient shown below (b).



a) CIIP case (Daytime)



b) CIIP case (Nighttime)

Figure 13. Diagnostic flowchart for pediatric chronic idiopathic intestinal pseudo-obstruction

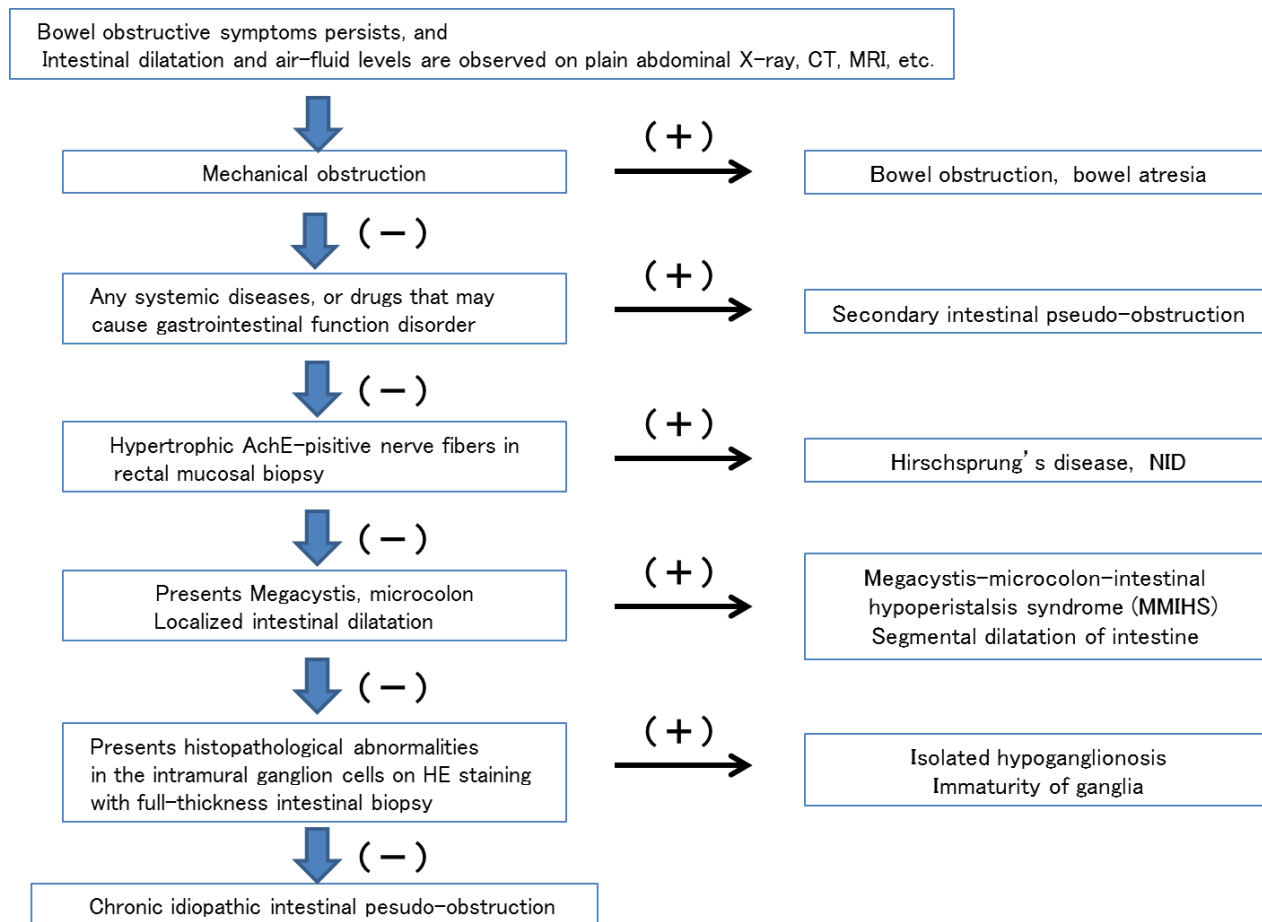


Figure 14. Diagnostic flowchart for chronic idiopathic intestinal pseudo-obstruction (for older children and adults)

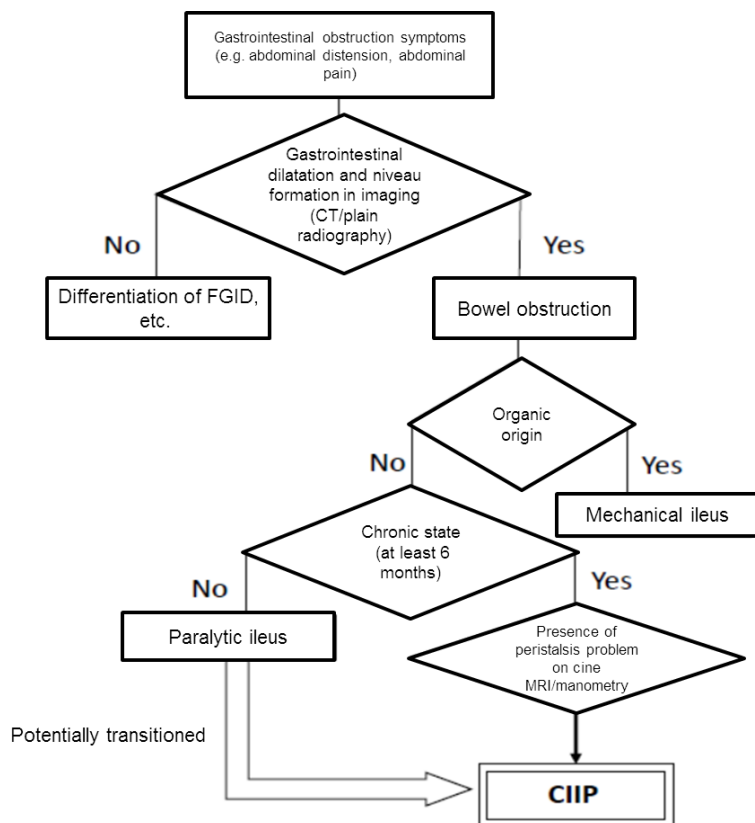
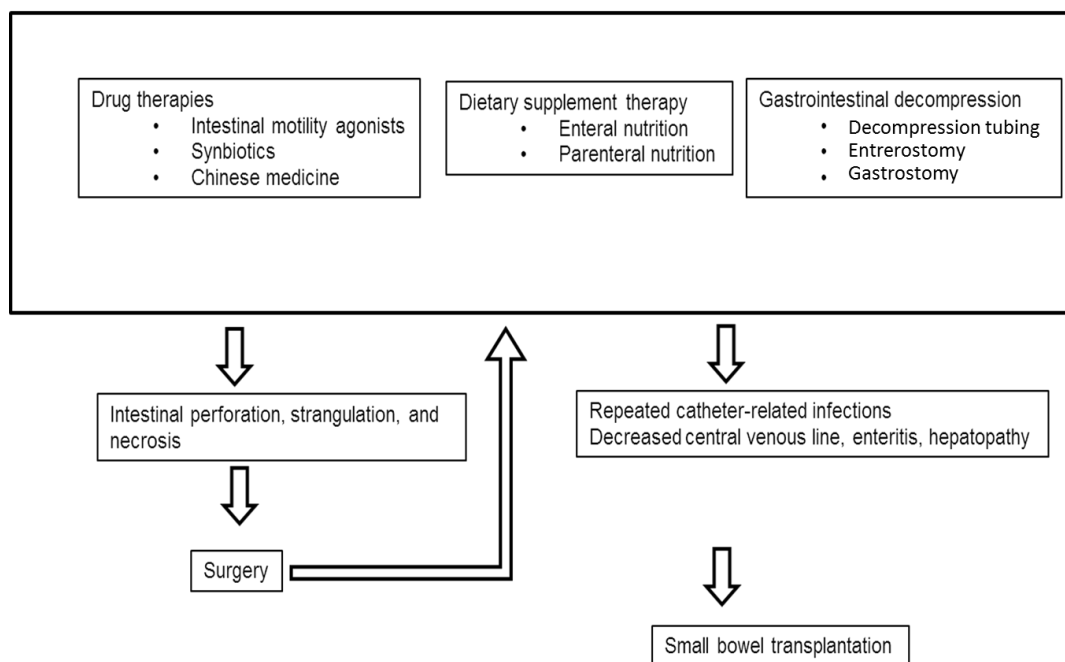


Figure 15. Treatment flowchart for chronic idiopathic intestinal pseudo-obstruction

Maintenance therapy



2. Coverage of the clinical practice guideline

1) *Within the scope of this guideline*

- a. All allied disorders of Hirschsprung's disease
- b. Diagnoses for patients suspected of being in this disease group
- c. Clinical history, physical findings, diagnostic imaging, histopathology for this disease group
- d. Treatment for patients with a definitive diagnosis of this disease
- e. Medications, enteral nutrition, parenteral nutrition, various gastrointestinal decompression methods, surgical treatment, and transplantation for this disease group
- f. Vital and functional prognoses for each disease

2) *Outside of the scope of this guideline*

- a. Hirschsprung's disease (aganglionosis)
- b. Primary intestinal pseudo-obstruction not included in this disease group
- c. Secondary intestinal pseudo-obstruction

3. CQ and systematic review

1) *Setting of CQ*

Four allied disorders of Hirschsprung's disease—immaturity of ganglia, IND, segmental dilatation of intestine, and IASA—show a good clinical course and are extremely rare; as such, these diseases are likely to rarely cause confusion when making therapeutic decisions in clinical practice.

Although the other three diseases—isolated hypoganglionosis, MMIHS, and CIIP—are also rare diseases, quite a few cases have been documented, and their clinical course is serious. These three diseases may therefore require the consideration of evidence and fair opinions from specialists when making decisions on their treatment in clinical practice. For these reasons, these three diseases were selected as targets of the clinical questions (CQs) of this guideline.

The following seven CQs were created, and the recommendations are posed individually for the three diseases.

2) *Systematic review*

- CQ1: How are isolated hypoganglionosis, MMIHS, and CIIP diagnosed?
- CQ2: What kind of drug therapy is recommended for the treatment of isolated hypoganglionosis, MMIHS, and CIIP?
- CQ3: Is gastrointestinal decompression therapy recommended for the treatment of isolated hypoganglionosis, MMIHS, and CIIP?
- CQ4: Is nutritional therapy recommended for the treatment of isolated hypoganglionosis, MMIHS, and CIIP?
- CQ5: Is (radical) surgical treatment recommended for the treatment of isolated hypoganglionosis, MMIHS, and CIIP?
- CQ6: Is small bowel transplantation recommended for the treatment of isolated hypoganglionosis, MMIHS, and CIIP?
- CQ7: What is the prognosis of isolated hypoganglionosis, MMIHS, and CIIP?

This guideline was developed using the methodologies in the "Minds Handbook for Clinical Practice Guideline Development 2014" and the "Minds Manual for Clinical Practice Guideline Development." However, as we expected difficulty in obtaining high-quality evidence on each disease, a unique approach was used for the systematic review.

There are only a few reports on the rare diseases in the CQs, so sometimes the three diseases were duplicated or confused in a single paper. In addition, a scoping search showed that a majority of the articles were case reports. Many of the case reports have descriptions on the diagnosis, treatment, prognosis, and complications. For these reasons, we decided that the search would be conducted not by each CQ but by three diseases collectively, and the outcomes would then be assigned to each CQ.

The databases used were PubMed and Ichu-Shi Web, the languages in the scope were Japanese and English, and search date was unlimited. A total of 1,477 articles were obtained, and 3 members of our group conducted primary screening, ultimately selecting 396 articles for secondary screening (**Tables 2, 3**). Secondary screening by 10 members resulted in dropping 108 articles, and the evidence table was developed based on the remaining 288 articles.

In the creation of the evidence table, when one article was applicable to two or more CQs, extra rows were set accordingly, and the applicable outcomes and conclusions were recorded. The completed evidence table was summarized by each CQ, and a "Summary by CQ" was created. The SR team then made systematic review reports by each CQ.

(1) Overview of the systematic review

Decisions prior to the literature search

Database used: PubMed and Ichu-Shi Web

Published year of literature in scope: All articles published through 2015

Search conditions of literature: Only humans used as research subjects

Language: Japanese and English

Diseases in scope: Three allied disorders of Hirschsprung's disease (isolated hypoganglionosis, MMIHS, and CIIP)

Overview of the literature search

Search by: Two members of the SR team (working independently)

Search formula: Refer to the materials (Database search results: **Tables 2, 3**, Literature search flowchart: **Figure 16**).

Number of articles: 1,488 (PubMed: 1,011 + Ichu-Shi Web: 477)

(2) Primary screening

Personnel in charge: Three members of the SR team

Screening method: The above-mentioned 3 members independently checked the titles and abstracts of

1488 articles. At this stage, articles clearly unrelated to the predetermined CQs were excluded. Articles for which the contents could not be judged based only on the title and abstract were included for review.

Primary screening result: After comparing the results from the 3 members, 396 out of 1,488 articles were ultimately selected for secondary screening.

(3) Secondary screening and creation of evidence table

Personnel in charge: 10 members of the SR team.

Screening method: 10 members above shared the screening of 396 articles. Full screening by checking the full texts determined which articles to choose based on the selection criteria.

Secondary screening result: After the SR team leader's review, 288 out of 396 articles were finally selected for evidence table creation.

Evidence table creation: From the 288 articles selected, 10 members extracted the details from them for a total of 836 pieces of evidence to create an evidence table. (Contents of the evidence table: bibliographic information, study design, PICO, conclusion, and CQs applicable)

(4) Evaluation and consolidation of evidence (creation of CQ summary)

Personnel in charge: SR team leader

Creation of CQ summary: The CQ summary was created by classifying the 836 pieces of evidence extracted by the 10 SR team members by CQ, target disease, and outcome and then summarizing by study design.

Significance of CQ summary creation: The applicable studies focused on rare diseases of allied Hirschsprung's diseases, and the majority of the target articles were case reports and case series. In order to utilize them without disregarding low-evidence-level studies, we adopted a method of carefully extracting evidence based on the CQ and target disease from each article and reorganized the findings as a CQ summary. This method visualized the total pieces of evidence and provided a value, which is different from conventional evidence-level, onto accumulated facts empirically obtained in clinical practice.

(5) Systematic review report

The contents of the CQ summary were recapitulated to make a systematic review report. For every comparison of CQs, the outcomes of benefits and harms were listed, and a consolidated document was created for the judgement of its usefulness.

4. Determination of recommendations regarding the finalization and implementation policy

1) Determination of recommendations

The evidence table, summary by CQ, and systematic review report created by SR team were submitted to the guideline development group, who created proposed recommendations and commentary based on the submitted materials. Since most of the evidence comprised case reports and case series, the strength of

the evidence was almost "D", but recommendations were created for the usefulness in clinical practice.

After a consensus meeting, the recommendations were determined by 13 guideline development committee members using the Delphi voting method via e-mail (**Table 4**). Two committee members in charge of clinical practices for the adult domain declined to vote due to their having limited clinical practice experience in the child domain. Several other committee members also declined to vote for the determination of recommendation on CQ in one's duty. At the first round of voting, all of the recommendations obtained 90% or greater approval.

2) Finalization

Between December 1 and December 31, 2016, a recommendation draft was posted on the homepages of the Japanese Society of Pediatric Surgeons; the Japanese Society for Pediatric Gastroenterology, Hepatology and Nutrition; and the Japanese Society of Neurogastroenterology to solicit public comments. It was finalized after an external evaluation by epidemiology specialists (**Table 5**).

3) Implementation

The detailed version was mailed to major medical institutions and, at the same time, published in research reports. The practical version was issued as a publication and also posted on the homepages of the Japanese Society of Pediatric Surgeons and the Japanese Society for Pediatric Gastroenterology, Hepatology and Nutrition for dissemination.

Table 2. Database search result 1

Title	Allied disorders of Hirschsprung's disease
CQ	
Database	PubMed
Date	2015/2/5
Searched by	FK/YA

#	Search formula	Number of literature
	<p>((("chronic intestinal pseudo-obstruction"[TIAB]) OR ("Intestinal Pseudo-Obstruction"[Mesh]) AND (chronic[TW]))) OR (((((((("Neuronal intestinal pseudoobstruction"[Supplementary Concept]) OR "Megacystis microcolon intestinal hypoperistalsis syndrome"[Supplementary Concept]) OR "intestinal dysganglionoses"[TIAB]) OR "Megacystis microcolon intestinal hypoperistalsis syndrome"[TIAB]) OR MMIHS[TIAB] OR "Neuronal intestinal pseudoobstruction"[TIAB]) OR "Chronic idiopathic intestinal pseudo-obstruction syndrome "[TIAB]) OR ((("Hirschsprung Disease"[Mesh]) OR ("Hirschsprung*" [TW])) AND ((allied[TIAB]) OR (variant[TIAB] OR variants[TIAB]))) OR ("Congenital idiopathic intestinal pseudoobstruction"[nm]) OR ((("Intestinal Pseudo-Obstruction"[Mesh]) AND (congenital[TIAB])) OR (immaturity[TIAB] AND ganglia[TW]) OR hypoganglionosis[TW] OR ("segmental dilation"[TIAB] AND intestine[TW]) OR ("internal anal sphincter"[TIAB] AND achalasia[TW]))) NOT (Animals[MH] NOT Humans[MH]) AND English[LA])</p>	1011

Table 3. Database search result 2

Title	Allied disorders of Hirschsprung's disease
CQ	
Database	Ichu-Shi Web
Date	2015/1/22
Searched by	FK/YA

#	Search formula	Number of literature
	(((CIPO/AL or (chronic/AL and (bowel obstruction-negative/TH or pseudoobstruction/AL))) or (((allied Hirschsprung's disease/AL) or (allied Hirschsprung's disease/AL) or (Immaturity/AL) or (hypoganglionosis/AL) or (neuronal/AL and intestinal/AL and dysplasia/AL) or ((megacystis-microcolon-intestinal hypoperistalsis syndrome/TH or MMIHS/AL)) or (anal achalasia/TH) or (CIIP/AL) or (chronic idiopathic intestinal pseudoobstruction/AL)))))) and (PT=except for minutes and CK=human))	477

Table 4. Voting result by guideline development group

	Number of votes	Number of approvals	Ratio (%)
CQ1-1	13	12	92.3
CQ1-2	13	13	100
CQ1-3	13	13	100
CQ2-1	13	13	100
CQ2-2	13	13	100
CQ2-3	13	13	100
CQ3-1	13	13	100
CQ3-2	13	13	100
CQ3-3	13	13	100
CQ4-1	13	13	100
CQ4-2	13	13	100
CQ4-3	13	12	92.3
CQ5-1	12	11	91.7
CQ5-2	12	12	100
CQ5-3	12	11	91.7
CQ6-1	13	13	100
CQ6-2	13	13	100
CQ6-3	13	13	100
CQ7-1	10	10	100
CQ7-2	10	10	100
CQ7-3	10	10	100

Table 5

Toshio Morizane Chief Visiting Researcher, Japan Council for Quality Health Care

External evaluation of the Clinical Practice Guideline

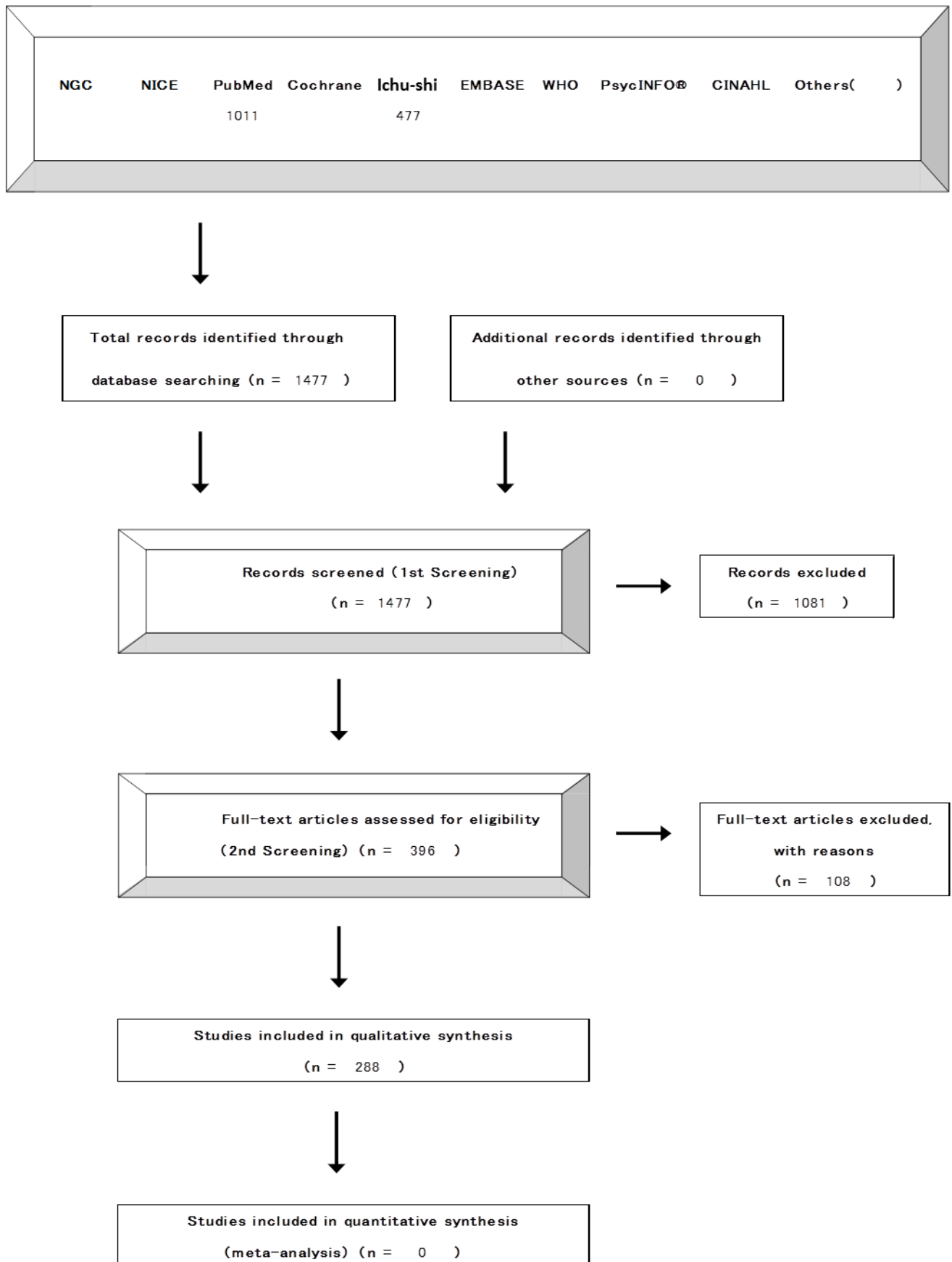
“It is logically summarized and presented with high relevance. This guideline describes the current issues and is considered to be highly useful in areas with poor evidence in clinical practice”.

number	Evaluated points	Evaluation	Comments
1	The scope to be handled in the whole medical treatment related to the target disease/health problem is clear (whole or part).	1 2 3 ④*	A thorough presentation of the medical treatment for Allied disorders of Hirschsprung's disease (the diagnosis, medication, surgical therapy, etc.)
2	The contents conform to the knowledge level of the target guideline users.	1 2 3 ④	Presentation of professional content that actually corresponds to the medical treatment
3	The magnitude and certainty of the effect of intervention (diagnosis, treatment, etc.) on the patient's outcomes are scientifically evaluated based on a systematic review (qualitative/quantitative).	1 2 3 ④	No CQs can be meta-analyzed. The strength of evidence is evaluated by the quantitative summarization of evidence related to the CQs from articles searched comprehensively.
4	The benefits and disadvantages (harm, burdens, expenses) of interventions are evaluated in an appropriate manner.	1 2 3 ④	Whether it is “useful” or “harmful” is evaluated quantitatively.
5	The strength of the recommendation is based on the importance of multiple outcomes, the magnitude and uncertainty of benefits and harms, and the cost effectiveness. It is also based on a comparison of multiple interventions, if necessary.	1 2 3 ④	Because the diseases mentioned here are rare, the need for a cost-effectiveness analysis is considered to be low.
6	The viewpoints of a multi-disciplinary supporting team as well as those of the subjects are reflected in the recommendation.	1 2 ③ 4	The provision of care requiring multi-disciplinary support, such as daily care management and home medical care, should be considered in a future study.
7	The individual recommendations correspond to the clinical questions, and the subjects, including attributes, are clear.	1 2 3 ④	Recommendations are presented based on each diagnosis and the patient's attributes.
8	The description of individual interventions is concrete and feasible. Facilities, staffs, equipments, etc. are also described, if necessary.	1 2 3 ④	As the target diseases are rare, it is assumed that care at facilities capable of advanced medical treatment including small intestine transplantation is a prerequisite.
9	Management is done so that the COI of the guideline creator does not affect the recommendation.	1 2 ③ 4	The creator has no COIs to disclose. Details about the management are unknown.

* Score: 1 Strongly Disagree, 2 Disagree, 3 Agree, 4 Strongly Agree

Figure 16. Literature search flowchart (allied disorders of Hirschsprung's disease)

[4-2. Literature search flowchart] PRISMA statement is modified.



VI. Recommendation

1. CQ1: How are isolated hypoganglionosis, MMIHS, CIIP diagnosed?

CQ1-1: How is isolated hypoganglionosis diagnosed?	
Recommendation: A full-thickness biopsy of the gastrointestinal tract (especially the small intestine and sigmoid colon) is recommended for the definitive diagnosis of isolated hypoganglionosis.	
Strength of recommendation	① (Strong): Recommend to “perform” or “not to perform” 2 (Weak) : Propose to “perform” or “not to perform”
Evidence	A (Strong) B (Moderate) ③ (Weak) D (Very weak)

Commentary

Isolated hypoganglionosis (HP) is the most difficult disease to diagnose among the allied disorders of Hirschsprung's disease. This is because the basic concept of HP is not clear, and a definitive method of diagnosis has not been clearly established. Reported diagnostic methods for HP include 1) plain abdominal X-ray, 2) gastrointestinal imaging, 3) manometry, 4) a rectal mucosal biopsy, and 5) a gastrointestinal full-thickness biopsy. Among these, many studies have shown that a full-thickness gastrointestinal biopsy (especially from the small and large bowels) was useful for diagnosing HP. This is because the definitive diagnosis of HP has been based on reduced neurocytes in the myenteric plexus (Auerbach's plexus) in many former reports. Some reports have shown that when it is difficult to assess the neurocyte distribution by HE staining, histochemical staining (such as AchE, NADPH, SDH, LDH, silver staining) is useful for the diagnosis.¹⁻³³⁾ In particular, a questionnaire survey conducted in 2012 for domestic pediatric surgery institutions in Japan reported that an intraoperative frozen section diagnosis had a low accuracy, and a pathological diagnosis by permanent preparation had 94% accuracy.³⁴⁾ Therefore, a gastrointestinal full-thickness biopsy has been considered useful in the diagnosis of HP. No complications have been reported in association with full-thickness biopsies.

As for the usefulness of a rectal mucosal biopsy, some reports have recommended a full-thickness biopsy for the final diagnosis of HP, as the former has low accuracy.^{18, 19, 34)} The reason is that the submucosal nerve plexus (Meissner's plexus) of HP is normal, and AchE staining is also negative or normal (i.e. it is useful for excluding Hirschsprung's disease, but not useful for the definitive diagnosis of HP).

In addition, plain abdominal radiography and gastrointestinal imaging may not be useful for the definitive diagnosis of HP. Findings obtained from these imaging examination such as the air-fluid level and gas-filled intestine on plain abdominal radiography, and intestinal dilatation, intestinal stenosis, megacolon, microcolon, and caliber change on gastrointestinal imaging are similar to those of other allied Hirschsprung's diseases. A diagnosis therefore cannot be determined by imaging studies alone. Such modalities may also increase unnecessary hazardous X-ray exposure.^{17, 34-38)}

The usefulness of manometry conducted for allied disorders of Hirschsprung's disease is uncertain. It

may indicate gastrointestinal dysfunction but has low accuracy due to non-constant results in neonatal population, such as reflex negativity, reflex positivity, or atypical reflex. Some articles have reported on esophageal and duodenal manometry, but irregular peristalsis observed in the upper gastrointestinal tracts is not specific to HP. Intestinal manometry is not thought to be useful in the diagnosis of HP.^{18, 21, 23, 24, 34, 37-39)}

In conclusion, the most useful examination in the diagnosis of HP is a full-thickness gastrointestinal biopsy, although a rectal mucosal biopsy can be performed first to rule out Hirschsprung's disease. Plain abdominal X-ray, barium enema, and rectal manometry are not useful for the definitive diagnosis of HP and may even cause harm due to X-ray exposure. However, those examinations may be useful for the differential diagnosis of other allied disorders of Hirschsprung's disease.

References

- 1) Ida S. 【Toward Seamless Medical Treatment from Pediatrics to Internal Medicine】 Particular Disease; Gastrointestinal Disease; Intestinal Failure (Long-term TPN Patient, Allied Hirschsprung disease, CIIP, etc.). *Diagnosis and Treatment*. 2013; 101: 1867-72. (Article in Japanese)
- 2) Sashiyama H, Tsujinaka Y, Hamahata Y, et al. A surgical case of colonic Segmental Hypoganglionosis. *J Jpn Soc Coloproctol*. 2013; 66: 263-8. (Article in Japanese)
- 3) Watanabe Y, Takasu H, Sumida W. A preliminary report on the significance of excessively long segment congenital hypoganglionosis management during early infancy. *J Pediatr Surg*. 2011; 46: 1572-7.
- 4) Wakatsuki K, Kaneizumi T, Yagura K, et al. A case of hypoganglionosis localized in the small intestine. *J Jpn Surg Assoc*. 2007; 68: 878-81. (Article in Japanese)
- 5) Meier-Ruge WA, Bruder E. Pathology of chronic constipation in pediatric and adult coloproctology. *Pathobiology*. 2005; 72): 1-102.
- 6) Tomita R, Munakata K, Howard ER, et al. Histological studies on Hirschsprung's disease and its allied disorders in childhood. *Hepatogastroenterology*. 2004; 51: 1042-4.
- 7) Tomita R, Ikeda T, Fujisaki S, et al. Hirschsprung's disease and its allied disorders in adults' histological and clinical studies. *Hepatogastroenterology*. 2003; 50: 1050-3.
- 8) Kobayashi H, Li Z, Yamataka A, et al. Overexpression of neural cell adhesion molecule (NCAM) antigens on intestinal smooth muscles in hypoganglionosis: is hypoganglionosis a disorder of the neuromuscular junction? *Pediatr Surg Int*. 2003; 19: 190-3.
- 9) Kobayashi H, Yamataka A, Lane GJ, et al. Pathophysiology of hypoganglionosis. *J Pediatr Gastroenterol Nutr*. 2002; 34: 231-5.
- 10) Rolle U, Yoneda A, Solari V, et al. Abnormalities of C-Kit-positive cellular network in isolated hypoganglionosis. *J Pediatr Surg*. 2002; 37: 709-14.
- 11) Munakata K, Fukuzawa M, Nemoto N. Histologic criteria for the diagnosis of allied diseases of Hirschsprung's disease in adults. *Eur J Pediatr Surg*. 2002; 12: 186-91.

- 12) Kubota A, Yamauchi K, Yonekura T, et al. Clinicopathologic relationship of hypoganglionosis. *J Pediatr Surg.* 2001; 36: 898-900.
- 13) Nogueira A, Campos M, Soares-Oliveira M, et al. Histochemical and immunohistochemical study of the intrinsic innervation in colonic dysganglionosis. *Pediatr Surg Int.* 2001; 17: 144-51.
- 14) Meier-Ruge WA, Brunner LA, Engert J, et al. A correlative morphometric and clinical investigation of hypoganglionosis of the colon in children. *Eur J Pediatr Surg.* 1999; 9: 67-74.
- 15) Watanabe Y, Ito F, Ando H, et al. Morphological investigation of the enteric nervous system in Hirschsprung's disease and hypoganglionosis using whole-mount colon preparation. *J Pediatr Surg.* 1999; 34: 445-9.
- 16) Hirobe S, Hayashi A, Kamakata S, et al. 【Total colon and extensive aganglionosis】 Experiences of advanced hypoganglionosis, especially on differentiation and association with aganglionosis. *Japanese Journal of Pediatric Surgery.* 1998; 30: 527-31. (Article in Japanese)
- 17) Puri P. Variant Hirschsprung's disease. *J Pediatr Surg.* 1997; 32: 149-57.
- 18) Tomita R, Munakata T. Transition in clinical practice of Pediatric Surgery - Pathophysiology of Allied disorders of Hirschsprung's disease in adults. *Japanese Journal of Pediatric Surgery.* 1997; 29: 713-21. (Article in Japanese)
- 19) Tomita R, Munakata T, Kurosu Y. Diagnosis of adulthood Hirschsprung's disease and Allied diseases from the histopathological view with rectal biopsy. *JJCS.* 1996; 21: 975-9. (Article in Japanese)
- 20) Yamataka A, Fujiwara T, Nishiye H, et al. Localization of intestinal pacemaker cells and synapses in the muscle layers of a patient with colonic hypoganglionosis. *J Pediatr Surg.* 1996; 31: 584-7.
- 21) Watanabe Y, Harada T. Measurement of upper gastrointestinal manometry in Allied disorders of Hirschsprung's disease. *Japanese Journal of Pediatric Surgery.* 1996; 28: 1062-6. (Article in Japanese)
- 22) Yamataka A, Fujiwara T, Sunakawa M, et al. Distribution of Peristaltic Pacemaker (C - KIT Positive) Cells in the Intestinal Tract with Hypoganglionosis. *Japanese Journal of Pediatric Surgery.* 1996; 28: 1058-61. (Article in Japanese)
- 23) Toyosaka A, Seki Y, Miura K, et al. Allied disorders of Hirschsprung's disease - Especially on Intramural neurocytosis, Hypoganglionosis. *Japanese Journal of Pediatric Surgery.* 1996; 28: 1037-47. (Article in Japanese)
- 24) Taguchi T, Suita S, Nakao M, et al. Temporal changes in the pathology of Allied disorders of Hirschsprung's disease. *Japanese Journal of Pediatric Surgery.* 1996; 28: 1029-36. (Article in Japanese)
- 25) Smith VV. Intestinal neuronal density in childhood: a baseline for the objective assessment of hypo- and hyperganglionosis. *Pediatr Pathol.* 1993; 13: 225-37.
- 26) Yamataka A, Miyano T, Urao M, et al. Distribution of neuromuscular junctions in the bowel affected by hypoganglionosis. *J Pediatr Gastroenterol Nutr.* 1993; 16: 165-7.
- 27) Meier-Ruge W. Epidemiology of congenital innervation defects of the distal colon. *Virchows Arch A Pathol Anat Histopathol.* 1992; 420: 171-7.
- 28) Meijers JH, Molenaar JC. Congenital malformation of the enteric nervous system: history, immunohistodiagnosis and experimental approaches. *Neth J Surg.* 1991; 43: 230-5.

- 29) Minowa Y, Nakata Y. A Case of allied disorder of Hirschsprung Disease Controlled Gastrostomy and enterostomy for 5 Years. *Japanese Journal of Pediatric Surgery*. 1990; 22: 280-4. (Article in Japanese)
- 30) Puri P, Fujimoto T. Diagnosis of allied functional bowel disorders using monoclonal antibodies and electronmicroscopy. *J Pediatr Surg*. 1988; 23: 546-54.
- 31) Ariel I, Hershlag A, Lernau OZ, et al. Hypoganglionosis of the myenteric plexus with normal Meissner's plexus: a new variant of colonic ganglion cell disorders. *J Pediatr Surg*. 1985; 20: 90-2.
- 32) Munakata K, Okabe I, Morita K. Histologic studies of rectocolic aganglionosis and allied diseases. *J Pediatr Surg*. 1978; 13: 67-75.
- 33) Kadair RG, Sims JE, Critchfield CF. Zonal colonic hypoganglionosis. *JAMA*. 1977; 238: 1838-40.
- 34) Watanabe Y, Kanamori Y, Uchida K, et al. Isolated hypoganglionosis: results of a nationwide survey in Japan. *Pediatr Surg Int*. 2013; 29: 1127-30.
- 35) Zhang HY, Feng JX, Huang L, et al. Diagnosis and surgical treatment of isolated hypoganglionosis. *World J Pediatr*. 2008; 4: 295-300.
- 36) Hayakawa K, Hamanaka Y, Suzuki M, et al. Radiological findings in total colon aganglionosis and allied disorders. *Radiat Med*. 2003; 21: 128-34.
- 37) Tomita R, Ikeda T, Fujisaki S, et al. Upper gut motility of Hirschsprung's disease and its allied disorders in adults. *Hepatogastroenterology*. 2003; 50: 1959-62.
- 38) Munakata K, Okabe I, Koshinaga T, et al. Diagnosis of Hypoganglionosis with contrast enema examination. *J.J.S.P.R.* 1989; 5: 124-5. (Article in Japanese)
- 39) Tomita R, Munakata K, Igarashi S, et al. Pathophysiological investigation of adult Hirschsprung's disease and Allied disease – consideration from manometry assessment. *JJCS*. 1997; 22: 744-75. (Article in Japanese)

CQ1-2: How is megacystis-microcolon-intestinal hypoperistalsis syndrome (MMIHS) diagnosed?	
Recommendation: For cases in which symptoms of bowel obstruction, such as abdominal distension and vomiting, are present during the neonatal period and no organic obstruction is observed, a gastrointestinal series is recommended. When a microcolon is observed and megalocystis is simultaneously confirmed by cystography or computed tomography (CT)/ultrasonography, MMIHS is strongly suspected. An intestinal full-thickness biopsy is recommended for the definitive diagnosis to differentiate it from other allied disorders of Hirschsprung's disease.	
Strength of recommendation	① (Strong): Recommend to “perform” or “not to perform” 2 (Weak): Propose to “perform” or “not to perform”
Evidence	A (Strong) B (Moderate) © (Weak) D (Very weak)

Commentary

Megacystis-microcolon-intestinal hypoperistalsis syndrome (MMIHS) is a serious syndrome with an unknown etiology. Bowel obstructive symptoms are noted from neonatal period, resulting in intestinal failure and accompanied by megalocystis and microcolon.

Diagnostic criteria:

- 1) Bowel obstruction symptoms such as abdominal distension, vomiting, and abdominal pain present immediately after birth
- 2) Megacystis present
- 3) Barium enema reveals microcolon in the neonatal period
- 4) No mechanical obstructive lesion observed in the gastrointestinal tract
- 5) No pathological abnormality observed in the neural plexus in specimen with a full-thickness intestinal biopsy

All five of these items need to be met.

Although plain abdominal X-ray is indispensable for the diagnosis of bowel obstruction, an extended gas pattern of the stomach and small bowel are general findings for bowel obstruction in neonates, so the diagnosis can rarely be determined based on X-ray findings alone. However, the observation of a lower abdominal mass shadow due to megalocystis on abdominal X-ray may be useful for the diagnosis.^{1, 2)}

Enema is useful for the confirmation of microcolon, an indispensable sign of this disease. Note that ileal atresia and Hirschsprung's disease (entire colon aganglionosis) also present with both gastrointestinal obstructive symptoms and microcolon during the neonatal period, so these diseases may be difficult to differentiate by contrast enema.

If megalocystis is indicated with the symptoms of gastrointestinal obstruction, MMIHS should be considered. Although cystography can be useful for a clear diagnosis of megalocystis, no further clinical information can be obtained using this modality. Ultrasonography or computed tomography (CT) can be alternative diagnostic imaging methods for the diagnosis of megalocystis.

Due to severe abdominal distension, laparotomy is performed during the neonatal period in many cases. MMIHS is often diagnosed based on the intra-operative findings. A full-thickness intestinal biopsy

is indispensable during laparotomy, as other allied disorders of Hirschsprung's disease, such as CIIP and isolated hypoganglionosis, must be differentiated. In addition, extensive Hirschsprung's disease and hypoganglionosis, can be differentiated with a full-thickness biopsy. MMIHS is characterized by the absence of abnormalities in ganglion cells.^{3, 4)} MMIHS must also be differentiated from CIIP, as neither of them have abnormalities in ganglion cells; the former can be distinguished by the presence of megalocystis and microcolon during the neonatal period. If possible, the ganglion cells should be checked using frozen sections and the histology should be confirmed using permanent preparations. No hypertrophic AcE-positive nerve fibers are seen in the rectal mucosa with a suction biopsy, so Hirschsprung's disease can be differentiated, but it is difficult to differentiate MMIHS from other allied disorders of Hirschsprung's disease using a suction biopsy.

Prenatal diagnoses have often been made in recent years based on a dilated intestinal tract and megalocystis.⁵⁻⁷⁾ Progressive cystectasy, hydroureteronephrosis, and gastrointestinal dilatation are characteristic findings in the prenatal period.

References

- 1) Tomita R, Morita K, Munakata K. On the significance of Peptidergic Nerve in Hirschsprung's disease and Hypoganglionosis. *Journal of Smooth Muscle Research*. 1989; 25: 147-54. (Article in Japanese)
- 2) Kupferman JC, Stewart CL, Schapfel DM, et al. Megacystis-microcolon-intestinal hypoperistalsis syndrome. *Pediatr Nephrol*. 1995; 9: 626-7.
- 3) Piotrowska AP, Rolle U, Chertin B, et al. Alterations in smooth muscle contractile and cytoskeleton proteins and interstitial cells of Cajal in megacystis microcolon intestinal hypoperistalsis syndrome. *J Pediatr Surg*. 2003; 38: 749-55.
- 4) Gomi A, Okamatsu T, Yatuka M, et al. Allied disorders of Hirschsprung's disease – Clinical course of MMIHS. *Japanese Journal of Pediatric Surgery*. 1996; 28: 1080-5. (Article in Japanese)
- 5) Tuzovic L, Anyane-Yeboa K, Mills A, et al. Megacystis-microcolon-intestinal hypoperistalsis syndrome: case report and review of prenatal ultrasonographic findings. *Fetal Diagn Ther*. 2014; 36: 74-80.
- 6) Dewan PA, Brown N, Murthy DP, et al. Hydrometrocolpos and segmental colonic dilatation in a girl with megacystis-microcolon-intestinal hypoperistalsis syndrome. *J Paediatr Child Health*. 1995; 31: 479-82.
- 7) Tanabe M, Takahashi H, Oonuma N, et al. Experience of treatment with Cisapride on Chronic Idiopathic Intestinal Pseudoobstruction (CIIP). *J. Jpn. Soc. Pediatr. Surg*. 1991; 27: 48-55. (Article in Japanese)

CQ1-3: How is chronic idiopathic intestinal pseudo-obstruction (CIIP) diagnosed?				
Recommendation: The duration of symptoms and the bowel obstruction conditions are determined from the clinical history and physical examination findings. The presence of intestinal dilatation, air-fluid level formation, and the absence of mechanical obstruction are confirmed by diagnostic imaging. For children, an intestinal full-thickness biopsy is recommended for the definitive diagnosis to differentiate it other allied disorders of Hirschsprung's disease. For adults, it is important to differentiate true mechanical obstruction and secondary intestinal pseudo-obstruction, and a full-thickness biopsy is not conducted as it is for children.				
Strength of recommendation	① (Strong): Recommend to <u>perform</u> or “not to perform” 2 (Weak): Propose to “perform” or “not to perform”			
Evidence	A (Strong)	B (Moderate)	C (Weak)	④ (Very weak)

Commentary

The diagnosis of CIIP requires all of the following 4 items to be met.

- 1) Chronic bowel obstruction observed
- 2) Intestinal dilatation and air-fluid levels on diagnostic imaging
- 3) No intramural obstruction of the gastrointestinal tract
- 4) Other diseases excluded

A duration of symptoms ≥ 2 months for children and ≥ 6 months for adults shall be confirmed.

Intestinal dilatation and air-fluid levels are diagnosed by plain abdominal X-ray, CT, MRI, or similar modalities.¹⁻⁴⁾ For neonates, radiological examinations in a standing or lateral decubitus position may be difficult, so the confirmation of air-fluid levels by plain abdominal X-ray is not necessarily required.

In the diagnosis of pediatric intestinal pseudo-obstruction, the location of dilated segments, the degree of peristaltic disorder, and the presence of non-mechanical obstruction can be detected based on the gastrointestinal gas pattern on plain abdominal X-ray and gastrointestinal series.^{1,4)} For adults, luminal obstructions caused by neoplastic lesions, inflammation, and adhesion need to be excluded.

The diagnosis of idiopathy requires the exclusion of other pseudo-obstructions.

For children, diseases classified as primary pseudo-obstructions need to be differentiated. Although congenital aganglionosis (Hirschsprung's disease) can be diagnosed by a suction rectal mucosal biopsy, a pathological evaluation by a full-thickness bowel biopsy is indispensable for the differential diagnosis of isolated hypoganglionosis and immaturity of ganglia.^{5,6)}

In adults, primary intestinal pseudo-obstructions other than CIIP are rare, and the exclusion of secondary pseudo-obstructions is emphasized in the diagnosis of idiopathy. The secondary pseudo-obstructions to be differentiated are listed in **Table 1**.

Cine MRI and intestinal manometry are useful for assessing peristaltic disorders present in CIIP, and these two examinations are used instead of a full-thickness biopsy in adults.⁷⁻¹¹⁾

References

- 1) Byrne WJ, Cipel L, Ament ME, et al. Chronic idiopathic intestinal pseudo-obstruction syndrome. Radiologic signs in children with emphasis on differentiation from mechanical obstruction. *Diagn Imaging*. 1981; 50: 294-304.
- 2) Orita T, Harafuji I, Matsumoto M, et al. A case of Chronic idiopathic intestinal pseudo-obstruction accompanied by Von Recklinghausen 's disease. *The Japanese Journal of Gastroenterological Surgery*. 1992; 25: 1334-8. (Article in Japanese)
- 3) Munoz-Yague MT, Solis-Munoz P, Salces I, Ballestin C, et al. Chronic intestinal pseudo-obstruction: a diagnosis to be considered. *Rev Esp Enferm Dig*. 2009; 101(5): 336-42.
- 4) Masuzawa Y, Iwamoto K, Ichida K, et al. A case considered as Chronic idiopathic intestinal pseudo-obstruction (CIIP) with significant flatulence. *Shin - senri hospital Medical Journal*. 1996; 7: 72-7. (Article in Japanese)
- 5) Muto M, Matsufuji H, Tomomasa T, et al. Pediatric chronic intestinal pseudo-obstruction is a rare, serious, and intractable disease: a report of a nationwide survey in Japan. *J Pediatr Surg*. 2014; 49(12): 1799-803.
- 6) Munoz-Yague MT, Solis-Munoz P, Salces I, et al. Chronic intestinal pseudo-obstruction: a diagnosis to be considered. *Rev Esp Enferm Dig*. 2009; 101(5): 336-42.
- 7) Tomomasa T. Findings from gastroduodenal manometry in Chronic idiopathic intestinal pseudo-obstruction - especially on phase 3. *Journal of Smooth Muscle Research*. 1993; 29: 204-6. (Article in Japanese)
- 8) Watanabe Y, Harada T, Murahashi O, et al. A new method of upper gastrointestinal manometry in assessment of pediatric gastrointestinal motility – the usefulness in diagnosis and treatment of functional ileus. *J. Jpn. Soc. Pediatr. Surg*. 1992; 28: 1115-20. (Article in Japanese)
- 9) Tsujikage S. Examination of gastrointestinal and urinary tract abnormalities in adults with chronic idiopathic intestinal pseudo-obstruction (CIIP). *Med. j. Osaka Univ*. 1991; 43: 31-43. (Article in Japanese)
- 10) Munoz-Yague MT, Marin JC, Colina F, et al. Chronic primary intestinal pseudo-obstruction from visceral myopathy. *Rev Esp Enferm Dig*. 2006; 98: 292-302.
- 11) Irtan S, Bellaiche M, Brasher C, et al. Stomal prolapse in children with chronic intestinal pseudoobstruction: a frequent complication? *J Pediatr Surg*. 2010; 45: 2234-7.

2. CQ2: What kind of drug therapy is recommended for the treatment of isolated hypoganglionosis, MMIHS, and CIIP?

CQ2-1: What kind of drug therapy is recommended for the treatment of isolated hypoganglionosis?				
Recommendation: No drug therapy is recommended for isolated hypoganglionosis at this point.				
Evidence	A (Strong)	B (Moderate)	C (Weak)	Ⓓ (Very weak)

Commentary

Drug therapies for isolated hypoganglionosis are performed in various institutions and include prokinetic agent, probiotics, Japanese herbal medicine (Daikenchuto), antibiotics, enemas, laxatives, and antidiarrheal drugs. However, no randomized controlled trial (RCT) or case series has described the efficacy of these treatments. There is only one case report on probiotics¹⁾, and one case report mentioning on the use of anticholinergic or prostaglandin preparation.²⁾

As mentioned, the efficacy of the Japanese herbal medicine (Daikenchuto), which is often used clinically in Japan, is still unknown. Regarding probiotics, a case report¹⁾ showed that the administration of probiotics increased the amount of enteral nutrition and decreased the frequency of enteritis, but no other reports have been found to support its results. Anticholinergic or prostaglandin preparation drugs may have no effect on improving the gastrointestinal motility in case of isolated hypoganglionosis²⁾, as only one report exists and the effectiveness is unclear. Note that no adverse events have been reported to be associated with any of the drugs mentioned above.

At present, based on the available evidence, no drug can be recommended as an effective agent, that improves gastrointestinal functional disorder or symptoms accompanying isolated hypoganglionosis.

References

- 1) Kiyohara Y, Nakanaga M, Takahashi T, et al. Usefulness of symbiotics for Allied disorders of Hirschsprung's disease. *The Journal of Japanese Society for Parenteral and Enteral Nutrition*. 2010; 25: 935-9. (Article in Japanese)
- 2) Nagoshi R, Onimoto H, Nagata I, et al. A case of Chronic intestinal pseudo-obstruction complicated with congenital central hypoventilation syndrome (Ondine's curse). *Journal of Saitama Children's Medical Center*. 1991; 8: 51-7. (Article in Japanese)

CQ2-2: What kind of drug therapy is recommended for megacystis-microcolon-intestinal hypoperistalsis syndrome (MMIHS)?				
Recommendation: Although the usefulness of Japanese herbal medicines (Daikenchuto) or probiotics has been reported as drug therapy for MMIHS, evidence is insufficient to recommend these therapies at present.				
Evidence	A (Strong)	B (Moderate)	C (Weak)	Ⓓ (Very weak)

Commentary

Prokinetic agents (e.g. cisapride, metoclopramide), probiotics, Japanese herbal medicine (Daikenchuto), antibiotics (e.g. erythromycin), enemas, laxatives, and antidiarrheal drugs are sometimes used to treat MMIHS. Some case reports have described their efficacies, but there are no RCTs or case series to support these findings. Prokinetic agents, such as cisapride (no longer marketed in Japan) and metoclopramide are sometimes used, and their effectiveness was investigated in six case reports.¹⁻⁶ All of the reports concluded that these agents are ineffective in improving gastrointestinal motility. For replacement of cisapride, mosapride, a serotonin receptor agonist is now available in the Japanese market. However, no reports have yet focused on the effect.

The Japanese herbal medicine (Daikenchuto) has been reported to be effective in four case reports.⁷⁻¹⁰ This agent reportedly induces improvement in the gastrointestinal motility and intestinal transit time⁷, an increased amount of enteral nutrition intake⁸, and improvement in bowel obstruction symptoms.^{9, 10} The effects of probiotics have been described in only one case report¹¹, in which probiotics were administered via lower jejunostomy to prevent enteritis, and enteritis did not develop. The effects of antibiotics have been described three case reports^{5, 6, 10}, in which the effectiveness of erythromycin was investigated, but the results did not show any effectiveness.

Some case reports have described the administration of pantothenic acid, prostaglandin¹², or a sympathetic blocker¹³, none of which had any effect to improve the gastrointestinal motility.

In conclusion, no drug therapy can be recommended, but the Japanese herbal medicine Daikenchuto and probiotics may be attempted, as their effectiveness has been described in some case reports. Note that no adverse events have been reported to be associated with any of the drugs mentioned above.

References

- 1) Al-Alaiyan S, Nazer H. Megacystis-microcolon-intestinal hypoperistalsis syndrome. *Ann Saudi Med.* 1996; 16: 353-5.
- 2) Couper RT, Byard RW, Cutz E, et al. Cardiac rhabdomyomata and megacystis-microcolon-intestinal hypoperistalsis syndrome. *J Med Genet.* 1991; 28: 274-6.
- 3) Goldberg M, Pruchniewski D, Beale PG, et al. Megacystis - microcolon-intestinal hypoperistalsis syndrome. *Pediatr Surg Int.* 1996; 11: 246-7.

- 4) Al Harbi A, Tawil K, Crankson SJ. Megacystis-microcolon-intestinal hypoperistalsis syndrome associated with megaesophagus. *Pediatr Surg Int.* 1999; 15: 272-4.
- 5) White SM, Chamberlain P, Hitchcock R, et al. Megacystis-microcolon-intestinal hypoperistalsis syndrome: the difficulties with antenatal diagnosis. Case report and review of the literature. *Prenat Diagn.* 2000; 20: 697-700.
- 6) Manop J, Chamnanvanakij S, Wattanasarn C. Megacystis microcolon intestinal hypoperistalsis syndrome (MMIHS): a case report in Thailand. *J Med Assoc Thai.* 2004; 87: 1385-8.
- 7) Kubo M, Yanai T. Experience of treatment with Daikenchuto for various cases of ileus. *Progress in Medicine.* 1997; 17: 2547-9. (Article in Japanese)
- 8) Kakita H, Ito K, Koide W, et al. A case of Megacystis Microcolon Intestinal Hypoperistalsis Syndrome, in which Daikenchuto was effective. *J Jpn Soc Perin Neon Med.* 2004; 40: 863-7. (Article in Japanese)
- 9) Iwashita K, Satake M, Kubo M. Problems on management of infants with Allied disorders of Hirschsprung's Disease. *The Journal of Yamanashi Central Hospital.* 2000; 27: 19-22. (Article in Japanese)
- 10) Hirakawa H, Ueno S, Matuda H, et al. Effect of the herbal medicine dai-kenchu-to on gastrointestinal motility in patients with megacystis-microcolon-intestinal hypoperistalsis syndrome (MMIHS) and chronic idiopathic intestinal pseudo-obstruction (CIIP): report of two cases. *Tokai J Exp Clin Med.* 2009; 34(1): 28-33.
- 11) Shimizu H, Ise K, Yamashita M, et al. A case of megacystis microcolon intestinal hypoperistalsis syndrome with successful surgical treatment. *J. Jpn. Soc. Pediatr. Surg.* 2013; 49: 1117-21. (Article in Japanese)
- 12) Kano T, Tateno Y, Anakura M, et al. A case of Megacystis-Microcolon-Intestinal Hypoperistalsis Syndrome(MMIHS). *The Journal of Clinical Pediatrics.* 1994; 42: 199-203. (Article in Japanese)
- 13) Berdon WE, Baker DH, Blanc WA, et al. Megacystis-microcolon-intestinal hypoperistalsis syndrome: a new cause of intestinal obstruction in the newborn. Report of radiologic findings in five newborn girls. *AJR Am J Roentgenol.* 1976; 126(5): 957-64.

CQ2-3: What kind of drug therapy is recommended for the treatment of chronic idiopathic intestinal pseudo-obstruction (CIIP)?

Recommendation: As drug therapies for CIIP, prucalopride, cisapride, Japanese herbal medicines (Daikenchuto), probiotics, and antibiotic (erythromycin) are sometimes used, and some reports have shown the usefulness of those agents for functional gastrointestinal disorder or abdominal symptoms. However, evidence is insufficient to recommend these therapies at present.

Evidence	A (Strong)	B (Moderate)	C (Weak)	Ⓓ (Very weak)
----------	------------	--------------	----------	---------------

Commentary

Some drugs are used to control CIIP, including prokinetic agents (e.g. prucalopride, cisapride), a Japanese herbal medicine (Daikenchuto), probiotics, antibiotics (e.g. erythromycin, polymyxin B), enema, laxatives, and antidiarrheals. However, there are few RCTs or case series to support the evidence, and most of the available articles are case reports.

The efficacy of prokinetic agents, such as prucalopride and cisapride (no longer marketed in Japan), have been reported. Prucalopride is a 5-HT₄ receptor agonist and unapproved in Japan. One case series report¹⁾ investigated the effectiveness of prucalopride in seven cases in their protocol, and three of four who completed the protocol showed improvement of obstructive symptoms. It should be noted that three patients withdrew from this protocol, but none of them had adverse events. In addition, one cross-sectional study²⁾ has reported improvement in bowel obstructive symptoms with cisapride. Furthermore, six case reports showed the usefulness of cisapride, including an increased amount of enteral nutrients^{3,4)}, reduction in the intestinal transit time⁵⁾, and improvement in bowel obstructive symptoms.⁶⁻⁸⁾ However, conversely, three case reports⁹⁻¹¹⁾ reported that cisapride was ineffective. The efficacy seems to vary depending on the pathology of individual cases. The effectiveness of mosapride, a serotonin receptor agonist now marketed in Japan to replace cisapride, for CIIP has not yet been reported.

Two case reports^{12, 13)} described the usefulness of the Japanese herbal medicine, Daikenchuto in improving gastrointestinal motility and bowel obstructive symptoms. However, one case report¹⁴⁾ found it to be ineffective. The evidence supporting the usefulness is thought to be scarce. Note that no adverse events have been reported to be associated with Daikenchuto.

Two case reports^{15, 16)} have described the efficacy of probiotics. In these reports, an increased intake of enteral nutrition and reduced incidence of enteritis were reported. Although there have been reports describing their ineffectiveness, the evidence supporting their effectiveness is not sufficient. Note that no adverse events have been reported to be associated with probiotics.

Regarding antibiotics, four case reports^{14,17-19)} showed the effectiveness of erythromycin. Erythromycin was administered with the expectation of enhancing intestinal motility, and most of these reports described increased enteral nutrition intake and improvement in bowel obstructive symptoms.

There have been no reports of ineffectiveness, nor any adverse events. Metronidazole and polymyxin B are administered to control the intestinal flora. Of the two drugs, only polymyxin B has been reported with regard to its efficacy against CIIP. However, findings have been conflicting; one case report²⁰⁾ described the improvement of symptoms, and two case reports^{21, 22)} indicated ineffectiveness. No adverse events were reported. Erythromycin may be effective, but the evidence is poor, and the efficacy of polymyxin B is considered unclear.

Regarding other drugs, one case report⁷⁾ found laxatives to be effective. Improvement in bowel obstructive symptoms by a cholinergic agent was shown in a case report⁸⁾, but this effect was denied in four other case reports.^{10,21-23)} The effectiveness of laxatives is therefore still unknown. Prostaglandin has also been used, and two case reports^{20, 22)} found that they improved bowel obstructive symptoms, but three reports^{3,20,24)} showed ineffectiveness. The effect of this drug in improving symptoms is also unknown. Buprenorphine, a weak opioid, was reported as an agent for relieving abdominal pain.²⁵⁾ Although evidence is not sufficient, it may be useful for relieving symptoms of abdominal pain associated with CIIP as well.

In conclusion, there are no recommended medications, but probiotics and erythromycin may be attempted, as their effectiveness has been shown in some case reports.

References

- 1) Munoz-Yague MT, Solis-Munoz P, Salces I, et al. Chronic intestinal pseudo-obstruction: a diagnosis to be considered. *Rev Esp Enferm Dig.* 2009; 101(5): 336-42.
- 2) Tanabe M, Takahashi H, Oonuma N, et al. Experience of Chronic Idiopathic Intestinal Pseudo-obstruction (CIIP) treated with Cisapride. *J. Jpn. Soc. Pediatr. Surg.* 1991; 27(1): 48-55. (Article in Japanese)
- 3) Yamamoto M, Arisawa K, Kumon Y, et al. A case of Chronic idiopathic intestinal pseudo-obstruction. *The Journal of the Hyogo Medical Association.* 1994; 37: 68-71. (Article in Japanese)
- 4) Horiuchi I, Ito H, Yamashita T, et al. A case of Chronic idiopathic intestinal pseudo-obstruction developed in neonatal period. *J. Jpn. Soc. Pediatr. Surg.* 1991; 27:48-55. (Article in Japanese)
- 5) Tanaka M, Matsuhashi N, Arai H, et al. A case of Chronic idiopathic intestinal pseudo-obstruction and reported cases in Japan. *Therapeutics.* 1987; 18: 537-40. (Article in Japanese)
- 6) Tomizuka H, Setoguchi Y, Ogura J, et al. A case of Chronic idiopathic intestinal pseudo-obstruction and medical treatments. *J. New Rem. & Clin.* 1989; 38: 158-65. (Article in Japanese)
- 7) Miyauchi K, Ooshima Y, Shimizu M, et al. A case of Chronic idiopathic intestinal pseudo-obstruction and investigation on reported cases in Japan. *Journal of Japanese Society of Gastroenterology.* 1991; 88: 1359-63. (Article in Japanese)
- 8) Ament ME, Vargas J. Diagnosis and management of chronic intestinal pseudo-obstruction syndromes in infancy and childhood. *Arq Gastroenterol.* 1988; 25: 157-65.

- 9) Suita R, Sai H, Izumi H. An autopsy case of Chronic idiopathic intestinal pseudo-obstruction syndrome (CIIPS). *Japanese Journal of Pediatrics*. 1983; 36: 135-42. (Article in Japanese)
- 10) Yahano S, Furuya S, Kadowaki H. Clinical course of 8 - year - old girl with CIIP and problems of long - term TPN support. *Japanese Journal of Pediatric Surgery*. 1983; 15: 1129-33. (Article in Japanese)
- 11) Ozawa M, Yamada R, Oohama M. Two cases of Chronic Idiopathic Intestinal Pseudo-obstruction Syndrome(CIIPS). *Japanese Journal of Pediatric Surgery*. 1983; 15: 1139-46 . (Article in Japanese)
- 12) Kubo M, Yanai T. Experiences of treatment with Daikenchuto for various kinds of ileus. *Progress in Medicine*. 1997; 17: 2547-9. (Article in Japanese)
- 13) Kubota A, Kawahara H, Hasegawa T, et al. Surgical intervention for chronic constipation. *Japanese Journal of Pediatric Surgery*. 2008; 40: 226-34. (Article in Japanese)
- 14) Hirakawa H, Ueno S, Matsuda H, et al. Effect of the herbal medicine Daikenchuto on gastrointestinal motility in patients with megacystis-microcolon-intestinal hypoperistalsis syndrome (MMIHS) and chronic idiopathic intestinal pseudo-obstruction (CIIP): report of two cases. *Tokai J Exp Clin Med*. 2009; 34(1): 28-33.
- 15) Kiyohara Y, Nakanaga M, Takahashi T, et al. The efficacy of symbiotics for allied Hirschsprung's disease. *J JSPEN*. 2010; 25: 935-9. (Article in Japanese)
- 16) Oonishi S, Wada H, Tamai S, et al. A case of CIIP who was struggling to treat weight gain and intestinal infection. *Kinki Shinseiji Kenkyukai Kaishi*. 2005; 14:24-8. (Article in Japanese)
- 17) Masuzawa Y, Iwamoto K, Ichida K, et al. A case considered as chronic idiopathic intestinal pseudo-obstruction (CIIP) with significant flatulence. *Shin - senri hospital Medical Journal*. 1996; 7: 72-7. (Article in Japanese)
- 18) Iwashita K, Satake M, Kubo M. Problems on management of Infants with Allied disorders of Hirschsprung's Disease. *The Journal of Yamanashi Central Hospital*. 2000; 27: 19-22. (Article in Japanese)
- 19) Dalgic B, Sari S, Dogan I, et al. Chronic intestinal pseudoobstruction: report of four pediatric patients. *Turk J Gastroenterol*. 2005; 16: 93-7.
- 20) Yoshida T, Murai K, Sugimoto S. Two cases considered to be Chronic idiopathic intestinal pseudo-obstruction. *Jpn J Clin Radiol*. 1997; 31(2): 335-8. (Article in Japanese)
- 21) Isa T, Muto Y, Hokama A . A case of Chronic idiopathic intestinal pseudo-obstruction (CIIP) with improved clinical symptoms by hyperbaric oxygen therapy. *The Japanese Journal of Clinical and Experimental Medicine*. 1989; 66: 2197-200. (Article in Japanese)
- 22) Michiura J, Katsumi M, Kawano N, et al. A case of Chronic idiopathic intestinal pseudo-obstruction with mitral valve divergence syndrome. *The Japanese Journal of Gastroenterological Surgery*. 1988; 21: 1134-7. (Article in Japanese)
- 23) Nozawa H, Hori T, Kubo K. An older child with Chronic idiopathic intestinal pseudo-obstruction presenting chronic constipation – Problems on diagnosis. *Japanese Journal of Pediatric Surgery*. 1983; 15: 1135-8. (Article in Japanese)

- 24) Tanaka T, Ootani K, Ando G, et al. A case of Chronic idiopathic intestinal pseudo-obstruction, *The Journal of the Tottori Medical Association*. 1989; 17: 54-9. (Article in Japanese)
- 25) Munoz-Yague MT, Marin JC, Colina F et al. Chronic primary intestinal pseudo-obstruction from visceral myopathy. *Rev Esp Enferm Dig*. 2006; 98(4): 292-302.

3. CQ3: Is gastrointestinal decompression therapy recommended for the treatment of isolated hypoganglioneosis, MMIHS, and CIIP?

CQ3-1: Is gastrointestinal decompression therapy recommended for the treatment of isolated hypoganglioneosis?	
Recommendation: Upper jejunostomy is proposed for isolated hypoganglioneosis. Ileostomy may be effective in some cases, but the efficacy of enterostomy at any other part of the intestinal tract is unknown.	
Strength of recommendation	1 (Strong): Recommend to “perform” or “not to perform” ② (Weak): Propose to “perform” or “not to perform”
Evidence	A (Strong) B (Moderate) © (Weak) D (Very weak)

Commentary

Isolated hypoganglioneosis is a disease that requires prolonged fasting and central venous nutrition management due to enteritis caused by stagnation of intestinal contents, subsequent sepsis, and abdominal pain. Effective gastrointestinal decompression may enable enteral feeding and provide the expectation of growth and a long-term survival. Enterostomy sites have been discussed in case series and case reports.

Regarding the type of gastrointestinal decompression, only one case has described gastrostomy with concomitant decompression via high jejunostomy; this approach enabled enteral nutrition¹⁾, and intestinal lavage was empirically performed in the reported case at the time of exacerbation. The prognosis varies depending on the location of the enterostomy, and effective usage of the enterostomy may enable enteral feeding in many cases. Compared with ordinary jejunostomy and ileostomy, high jejunostomy is significantly more effective with regard to X-ray findings, the survival rate²⁾, and the incidence of bowel obstruction³⁾, with good outcomes.^{4, 5)} The effectiveness of ileostomy is unclear. There have been cases requiring ileectomy due to functional failure⁶⁾, and enterostomy was re-performed at a higher position³⁾. However, there was also a case of improved bowel obstruction⁴⁾. There are no reports of effective colostomy, and additional enterostomy was required in the reported cases.^{3, 7)}

References

- 1) Minowa Y, Nakata K. A case of allied disorder of Hirschsprung’s disease controlled with gastrostomy and enterostomy for 5 Years. Japanese Journal of Pediatric Surgery. 1990; 22(3) : 280-4. (Article in Japanese)
- 2) Watanabe Y, Sumida W, Takasu H, et al. Early jejunostomy creation in cases of isolated hypoganglioneosis: verification of our own experience based on a national survey. Surg Today. 2015; 45: 1509-12.
- 3) Watanabe Y, Kanamori Y, Uchida K, et al. Isolated hypoganglioneosis: results of a nationwide survey in Japan. Pediatr Surg Int. 2013; 29: 1127-30.
- 4) Nishijima E, Oono K, Yoshioka T, et al. A case of Hypoganglioneosis in 6 - year - old girls, is it possible to close ileostomy? - Evaluation of peristalsis and defecation of the remaining residual bowel with artificial

valves. *The Medical Frontline*. 1991; 46(12): 2514-5. (Article in Japanese)

5) Minowa Y, Nakata K. A case of allied disorder of Hirschsprung's disease controlled with gastrostomy and enterostomy for 5 Years. *Japanese Journal of Pediatric Surgery*. 1990; 22(3) : 280-4. (Article in Japanese)

6) Miura H, Ooi R, Sogi N. Allied disorders of Hirschsprung's diseases – 3D structures of Auerbach plexus in Hypoganglionosis. *Japanese Journal of Pediatric Surgery*. 1996; 28 : 1048-52. (Article in Japanese)

7) Watanabe Y, Harada T. Upper gastrointestinal manometry in allied disorders of Hirschsprung's disease. *Japanese Journal of Pediatric Surgery*. 1996 ; 28: 1062-6. (Article in Japanese)

CQ3-2: Is gastrointestinal decompression therapy recommended for the treatment of megacystis-microcolon-intestinal hypoperistalsis syndrome (MMIHS)?				
Recommendation: No evidence supports the positive recommendation of gastrointestinal decompression for MMIHS.				
Evidence	A (Strong)	B (Moderate)	C (Weak)	Ⓓ (Very weak)

Commentary

MMIHS is a serious disease that requires prolonged fasting and central venous nutrition management due to enteritis caused by peristaltic disorder, subsequent sepsis, and abdominal pain.

Regarding gastrointestinal decompression therapy for MMIHS, some reports have shown that tube decompression did not improve the symptoms¹⁾, and enteral feeding was not enabled by decompression via gastrostomy, even with simultaneous enterostomy²⁾, despite its efficacy for isolated hypoganglionosis. Regarding intestinal lavage, there was a case³⁾ in which switching to antegrade lavage by Malone surgery after transanal lavage resulted in being able to provide home care to the patient. Regardless of the enterostomy site, enterostomy can only temporarily⁴⁾ or partially⁵⁾ relieve symptoms and does not contribute to prognostic improvement.⁶⁾ Colostomy is ineffective.⁴⁾ No side effects or adverse events accompanying decompression therapy have been reported.

References

- 1) Al Harbi A, Tawil K, Crankson SJ: Megacystis-microcolon-intestinal hypoperistalsis syndrome associated with megaesophagus. *Pediatr Surg Int.* 1999; 15: 272-4.
- 2) Berdon WE, Baker DH, Blanc WA, et al. Megacystis-microcolon-intestinal hypoperistalsis syndrome: a new cause of intestinal obstruction in the newborn. Report of radiologic findings in five newborn girls. *AJR Am J Roentgenol.* 1976; 126: 957-64.
- 3) Shimizu H, Ise K, Yamashita M, et al. A case of Megacystis-microcolon-intestinal hypoperistalsis syndrome in which surgical treatment was successful. *J. Jpn. Soc. Pediatr. Surg.* 2013; 49: 1117-1121. (Article in Japanese)
- 4) Goldberg M, Pruchniewski D, Beale PG, et al. Megacystis - microcolon - intestinal hypoperistalsis syndrome. *Pediatr Surg Int.* 1996; 11: 246-7.
- 5) Hirakawa H, Ueno S, Matuda H, et al. Effect of the herbal medicine Dai-kenchu-tou on gastrointestinal motility in patients with Megacystis-microcolon-intestinal hypoperistalsis syndrome (MMIHS) and Chronic idiopathic intestinal pseudo-obstruction (CIIP): report of two cases. *Tokai J Exp Clin Med.* 2009; 34: 28-33.
- 6) Manop J, Chamnanvanakij S, Wattanasarn. Megacystis-microcolon-intestinal hypoperistalsis syndrome (MMIHS): a case report in Thailand. *J Med Assoc Thai.* 2004; 87: 1385-8.

CQ3-3: Is gastrointestinal decompression effective for chronic idiopathic intestinal pseudo-obstruction (CIIP)?				
Recommendation: Intermittent decompression via enteric tube may be effective in some CIIP cases, and enterostomy may be effective in other cases. The appropriate approach should be considered on a case-by-case basis.				
Strength of recommendation	1 (Strong): Recommend to “perform” or “not to perform” ② (Weak): Propose to “perform” or “not to perform”			
Evidence	A (Strong)	B (Moderate)	C (Weak)	Ⓓ (Very weak)

Commentary

CIIP is a disease that requires repeated, prolonged fasting and central venous nutrition management due to enteritis caused by stagnation of intestinal contents, subsequent sepsis, and abdominal pain. Effective gastrointestinal decompression may enable enteral feeding and provide the expectation of growth and long-term survival. However, which type of gastrointestinal decompression therapy is most effective depends on each case.

Tube decompression as a gastrointestinal decompression therapy for CIIP reported to be effective in some cases and ineffective in others. One case reported that the bowel obstruction symptoms were remitted with nasogastric tube and enteral nutrition was enabled, but the bowel obstruction symptoms relapsed.¹⁾ For ileus tube, there was a case of marked improvement in abdominal distension and abdominal pain²⁾; however, there have been some cases of ineffectiveness³⁾ and no improvement in intestinal dilatation.⁴⁾ There have been cases in which the oral intake was enabled by intestinal lavage and continuous decompression through enterostomy⁵⁾, in which high jejunostomy temporarily improved bowel obstruction symptoms and enabled a small amount of oral intake⁶⁾, and in which ileostomy was effective.^{4, 6)} Nevertheless, the ineffectiveness of enterostomy has also been reported.⁷⁾ Colostomy has not been shown to be effective in any cases and has been reported not to have improved bowel obstruction symptoms even with simultaneous ileostomy.⁶⁾ No side effects or adverse events accompanying decompression therapy have been reported.

References

- 1) Tachibana M, Nakazawa Y, Sakamoto Y, et al. A case of Chronic idiopathic intestinal pseudo-obstruction: its complications and problems on long-term management. *Gastroenterology*. 1987; 6: 421-8. (Article in Japanese)
- 2) Tanaka M, Matsuhashi N, Arai H, et al. A case of Chronic idiopathic intestinal pseudo-obstruction and cases in Japan. *Therapeutics (Chiryogaku)*. 1987; 18: 537-40. (Article in Japanese)
- 3) Michiura H, Katsumi M, Kawano N, et al. A case of Chronic idiopathic intestinal pseudo-obstruction with mitral valve divergence syndrome. *The Japanese Journal of Gastroenterological Surgery*. 1988; 21: 1134-7. (Article in Japanese)
- 4) Matsuura A, Kikuchi T, Ooshima T, et al. A case of Chronic idiopathic intestinal pseudo-obstruction with transverse colonic axial torsion. *J Abdom Emerg Med*. 1996; 16(7): 1321-4. (Article in Japanese)
- 5) Nishijima E, Anpuku M, Higashimoto Y, et al. Treatment experience of Chronic idiopathic intestinal pseudo-obstruction (CIIPS) - Complications and problems on nutritional management of 8 cases developed in infancy. *JJPEN: The Japanese Journal of Parenteral and Enteral Nutrition*. 1992; 14:

1395-401. (Article in Japanese)

6) Kubota A, Okuyama H, Takahashi T, et al. **【Pathology and Treatment of Intestinal Torsion in Children】** A Case Report of CIIPS caused by intestinal malrotation - Consideration on the Difference Between CIIPS and MMIHS. *Japanese Journal of Pediatric Surgery*. 2005; 37: 824-31. (Article in Japanese)

7) Hirakawa H, Ueno S, Matuda H, et al. Effect of the herbal medicine dai-kenchu-to on gastrointestinal motility in patients with megacystis-microcolon-intestinal hypoperistalsis syndrome (MMIHS) and chronic idiopathic intestinal pseudo-obstruction (CIIP): report of two cases. *Tokai J Exp Clin Med*. 2009; 34: 28-33.

4. CQ4: Is nutrition therapy recommended for isolated hypoganglionosis, MMIHS, and CIIP ?

CQ4-1: Are enteral nutrition and parenteral nutrition effective as nutritional therapies for isolated hypoganglionosis?	
Recommendation: Enteral nutrition and parenteral nutrition are recommended as nutritional therapies for isolated hypoganglionosis.	
Strength of recommendation	① (Strong): Recommend to “perform” or “not to perform” 2 (Weak): Propose to “perform” or “not to perform”
Evidence	A (Strong) B (Moderate) C (Weak) ④ (Very weak)

Commentary

Aside from a few case reports, few papers have discussed nutritional therapy for isolated hypoganglionosis. The evidence level is very low. However, for this disease, which can develop during the neonatal period, parenteral nutrition therapy is clinically performed from an early stage in most of the cases, and enteral feeding therapy is combined with it once the disease condition is stabilized after stoma construction. Recommending parenteral nutrition and enteral nutrition as nutritional treatments is considered to be appropriate.

For parenteral nutrition, there are reports in which intermittent central venous nutrition was useful for preventing hepatic dysfunction¹⁾ and in which home total parenteral nutrition using an implanted central vascular catheter was useful.²⁾ As central venous nutrition may be an indispensable and long-term nutrition treatment for this disease, its complications need to be well recognized for its safe implementation. Furthermore, since it is a long-term therapy, a catheter with a cuff or an implanted central vascular catheter needs to be used for infection prevention, and home total parenteral nutrition should also be taken into consideration.

Enteral nutrition has never been specifically reported in papers, and the clinical managements depend on the efforts and ideas of each institution. Because a small intestinal stoma is constructed in many cases at present, some kind of enteral nutrition may be indispensable. Although breast milk, adjusted milk, semidigested nutrient, digestive nutrient, and elemental diet have all been appropriately used as enteral nutrients, the most appropriate nutrient has not yet been determined.

Nutritional therapy should be considered in combination with surgical treatment and medications for this disease.

References

- 1) Yamauchi K, Suita S, Sakaguchi T, et al. Investigation of a normalized case of advanced liver dysfunction due to parenteral nutrition. *The Journal of Japanese Society for Parenteral and Enteral Nutrition*. 1993; 8: 72-5. (Article in Japanese)
- 2) Iida N, Ogita K, Kai H. Home parenteral nutrition – treatment for short bowel syndrome. *Japanese Journal of Pediatric Surgery*. 2006; 38: 1061-7. (Article in Japanese)

CQ4-2: Are enteral nutrition and parenteral nutrition useful as nutritional therapies for megacystis-microcolon-intestinal hypoperistalsis syndrome (MMIHS)?				
Recommendation: Enteral nutrition and parenteral nutrition are recommended as nutritional therapies for MMIHS.				
Strength of recommendation	① (Strong): Recommend to “perform” or “not to perform” 2 (Weak): Propose to “perform” or “not to perform”			
Evidence	A (Strong)	B (Moderate)	C (Weak)	④ (Very weak)

Commentary

This disease is still a disease with a poor prognosis, and peristalsis dysfunction with unknown etiology develops during the neonatal period. A nationwide survey in Japan showed that total parenteral nutrition (TPN) was needed for 4 cases and a combination of parenteral and enteral nutrition was needed for 12 cases out of 19 definitively diagnosed cases. In 7 out of the 9 surviving cases at present, parenteral nutrition has been required. Based on these survey results and the fact that saving the lives of children with MMIHS is clinically difficult without enteral and parenteral nutrition support, parenteral and enteral nutrition are deemed appropriate for this disease, although the evidence level is low.

Three articles support the usefulness of parenteral nutrition: one reported on the promotion of growth hormone secretion with nocturnal cyclic TPN¹⁾, another showed its usefulness over a short period of time²⁾, and another reported on the long-term survival on cyclic TPN.³⁾ However, there have been reports of associated adverse events, including repeated catheter-related bloodstream infection caused by long-term central venous nutrition⁴⁻⁷⁾, cholestatic hepatic dysfunction^{6,8-10)}, the development of portal hypertension symptoms¹¹⁾, and copper deficiency.¹²⁾ When providing parenteral nutrition, clinicians should be familiar with the risk of those adverse events and perform appropriate preventative measures and treatments.

The usefulness of enteral nutrition has been reported.¹³⁾ The effectiveness of combination with parenteral nutrition has also been reported.^{14, 15)} However, these findings have been cited in a limited number of case reports and the evidence level is low. Regarding enteral nutrition for this disease, effective methods and appropriate nutrients need to be determined in the future.

References

- 1) Yokoyama S, Hirakawa H, Soeda J, et al. Twenty-four-hour profile of growth hormone in cyclic nocturnal total parenteral nutrition. *Pediatrics*. 1997; 100: 973-6.
- 2) Shikano T, Tateno Y, Anakura M, et al. A case of Megacystis-Microcolon-Intestinal Hypoperistalsis Syndrome (MMIHS). *The Journal of Clinical Pediatrics*, Sappo. 1994; 42: 199-203. (Article in Japanese)
- 3) Yokoyama S, Fujimoto T, Tokuda Y, Mitomi T: Successful nutrition management of megacystis-microcolon-intestinal hypoperistalsis syndrome - a case report. *Nutrition*. 1989; 5: 423-6.
- 4) Nazer H, Rejjal A, Abu-Osba Y, et al. Megacystis-microcolon-intestinal hypoperistalsis syndrome. *Saudi J Gastroenterol*. 1995; 1: 180-3.

- 5) Goldberg M, Pruchniewski D, Beale PG, et al. Megacystis - microcolon - intestinal hypoperistalsis syndrome. *Pediatr Surg Int.* 1996; 11: 246-7.
- 6) Shinkai M. A new treatment for children with intestinal failure – An effect of omega-3 lipid emulsion on children with intestinal failure associated liver disease. *Kanagawa Children's Medical Center Journal.* 2011; 40: 316-8. (Article in Japanese)
- 7) Kaida S, Mizote H, Tanaka Y, et al. Efficacy of Broviac catheter for children with MMIHS requiring long-term TPN. *J. Jpn. Soc. Surg. Infect.* 2003; 15: 119-22. (Article in Japanese)
- 8) Lee NC, Tiu CM, Soong WJ, et al. Megacystis-microcolon-intestinal hypoperistalsis syndrome: report of one case. *Acta Paediatr Taiwan.* 2003; 44: 238-41.
- 9) Masetti M, Rodriguez MM, Thompson JF, et al. Multivisceral transplantation for megacystis microcolon intestinal hypoperistalsis syndrome. *Transplantation.* 1999; 68: 228-32.
- 10) Iihoshi Y, Okada A. Hepatic disorders in long-term survivor of allied disorders of Hirschsprung's disease. *Japanese Journal of Pediatric Surgery.* 1996; 28: 1104-7. (Article in Japanese)
- 11) Kohler M, Pease PW, Upadhyay V. Megacystis-microcolon-intestinal hypoperistalsis syndrome (MMIHS) in siblings: case report and review of the literature. *Eur J Pediatr Surg.* 2004; 14: 362-7.
- 12) Tokuda Y, Yokoyama S, Tsuji M, et al. Copper deficiency in an infant on prolonged total parenteral nutrition. *JPEN J Parenter Enteral Nutr.* 1986; 10: 242-4.
- 13) White SM, Chamberlain P, Hitchcock R, et al. Megacystis-microcolon-intestinal hypoperistalsis syndrome: the difficulties with antenatal diagnosis. Case report and review of the literature. *Prenat Diagn.* 2000; 20: 697-700.
- 14) Gillis DA, Grantmyre EB. Megacystis-microcolon-intestinal hypoperistalsis syndrome: survival of a male infant. *J Pediatr Surg.* 1985; 20: 279-81.
- 15) Kaida S, Mizote H, Tanaka Y, et al. Efficacy of Broviac catheter for children with MMIHS requiring long-term TPN. *J. Jpn. Soc. Surg. Infect.* 2003; 15: 119-22. (Article in Japanese)

CQ4-3: Are enteral nutrition and parenteral nutrition effective as nutritional therapies for chronic idiopathic intestinal pseudo-obstruction (CIIP)?				
Recommendation: Enteral nutrition and parenteral nutrition are recommended as nutritional therapies for CIIP.				
Strength of recommendation	① (Strong): Recommend to “perform” or “not to perform” 2 (Weak): Propose to “perform” or “not to perform”			
Evidence	A (Strong)	B (Moderate)	C (Weak)	④ (Very weak)

Commentary

This disease may develop in neonates or older children. In both cases, intestinal peristaltic disorder may persist over a long period of time, and some kind of nutritional therapy is indispensable.¹⁻³⁾ Thus, the recommendation of nutritional therapy for this disease is deemed appropriate. While the evidence level may be weak, as most of the evidence supporting the application of nutritional therapy for this disease is from case reports, like for isolated hypoganglionosis and MMIHS the number of reports is slightly higher, and some reviews have been written.

Nine articles have described the usefulness of parenteral nutrition.⁴⁻¹²⁾ The usefulness reported includes the effect of fatty acid emulsion on hepatic steatosis, improvement of bowel obstruction symptoms, and improvement in the quality of life by cyclic TPN using an implanted central vascular catheter. However, there are some case reports and reviews¹³⁻¹⁵⁾ regarding adverse events, such as trace element deficiency, electrolyte disturbance, and sudden death due to trace element deficiency on long-term central venous nutrition. Since this disease may have a long duration of symptoms, special attention needs to be paid to the complications related to long-term parenteral nutrition.

The efficacy of enteral nutrition was reported in seven case reports and one review.^{5,9,12,14,16-19)} Its usefulness has been reported with respect to the use of semidigested nutrients, concomitant use of semidigested nutrients and a low-residue diet, use of semidigested nutrients and/or digestive nutrients, and a reduction in the frequency of ileus symptoms with semidigested nutrients. Furthermore, two articles describe the usefulness of concomitant parenteral and enteral nutrition. However, a lack of any marked contribution of enteral nutrition to the improvement in bowel obstruction symptoms has also been reported.⁸⁾ Although some trends support the efficacy of semi-digested nutrients or digestive nutrients, they may not be able to be administered in cases with aggravated symptoms. Further investigation into what kinds of enteral nutrients are most useful is needed.

References

- 1) Antonucci A, Fronzoni L, Cogliandro L, et al. Chronic intestinal pseudo-obstruction. *World J Gastroenterol*, 2008; 14: 2953-61.
- 2) Munoz-Yague MT, Marin JC, Colina F, et al. Chronic primary intestinal pseudo-obstruction from visceral myopathy. *Rev Esp Enferm Dig*. 2006; 98:292-302.
- 3) Iida H, Inamori M, Sekino Y, et al. A review of the reported cases of chronic intestinal pseudo-obstruction in Japan and an investigation of proposed new diagnostic criteria. *Clinical Journal of*

Gastroenterology. 2011; 4: 141-6.

- 4) Reif S, Tano M, Oliverio R, et al. Total parenteral nutrition-induced steatosis: reversal by parenteral lipid infusion. *JPEN J Parenter Enteral Nutr.* 1991; 15:102-4.
- 5) Gillis DA, Grantmyre EB: Megacystis-microcolon-intestinal hypoperistalsis syndrome: survival of a male infant. *J Pediatr Surg.* 1985; 20: 279-81.
- 6) Kubota A, Okuyama H, Takahashi T, et al. **【Pathology and Treatment of Intestinal Torsion in Children】** A Case Report of CIIPS caused by intestinal malrotation - Consideration on the Difference Between CIIPS and MMIHS. *Japanese Journal of Pediatric Surgery.* 2005; 37: 824-31. (Article in Japanese)
- 7) Yahano S, Furuya S, Kadowaki H. A case of 8-year-old girl with CIIP – Clinical course and problems on long-term TPN. *Japanese Journal of Pediatric Surgery.* 1983; 15: 1129-33. (Article in Japanese)
- 8) Ozawa M, Yamada R, Oohama M. Two cases of Chronic Idiopathic Intestinal Pseudo-obstruction Syndrome (CIIPS). *Japanese Journal of Pediatric Surgery.* 1983; 15: 1139-46. (Article in Japanese)
- 9) Horiuchi I, Ito H, Yamashita T, et al. A case of Chronic idiopathic intestinal pseudo-obstruction developed in neonates. *J. Jpn. Soc. Pediatr. Surg.* 1992; 28: 1359-63. (Article in Japanese)
- 10) Tachibana M, Nakazawa Y, Sakamoto Y, et al. A case of Chronic idiopathic intestinal pseudo-obstruction – Complications and problems on long-term management. *Gastroenterology.* 1987; 6: 421-8. (Article in Japanese)
- 11) Kume M, Iwasa M, Yamamoto A, et al. An example of Chronic idiopathic intestinal pseudo-obstruction reintegrated by long-term home parenteral nutrition (HPN). *The Journal of Japanese Society for Parenteral and Enteral Nutrition.* 1996; 11: 46-9. (Article in Japanese)
- 12) Ament ME, Vargas J: Diagnosis and management of chronic intestinal pseudo-obstruction syndromes in infancy and childhood. *Arq Gastroenterol.* 1988; 25: 157-65.
- 13) Tsuda K, Yokoyama Y, Kouzaki T, et al. A case of Selenium deficiency with Chronic idiopathic intestinal pseudo-obstruction on long-term Home parenteral nutrition. *Clinics in Gastroenterology.* 1997; 2: 73-7. (Article in Japanese)
- 14) Michiura H, Katsumi M, Kawano N, et al. A case of Chronic idiopathic intestinal pseudo-obstruction with mitral valve divergence syndrome. *The Japanese Journal of Gastroenterological Surgery.* 1988; 21: 1134-7. (Article in Japanese)
- 15) Suita R, Sai H, Izumi H. An autopsy case of Chronic idiopathic intestinal pseudo-obstruction syndrome (CIIPS). *Japanese Journal of Pediatrics.* 1983; 36: 135-42. (Article in Japanese)
- 16) Adachi Y, Yabana T, Koorito S. A Case of Chronic Idiopathic Intestinal Obstruction in Sjogren's Syndrome. *Journal of Japanese Society of Gastroenterology.* 1990; 87: 1223-7. (Article in Japanese)
- 17) Asabe H, Nagasaki A, Yamada K, et al. An experience of Chronic idiopathic intestinal pseudo-obstruction and investigation of cases in Japan. *Japanese Journal of Pediatric Medicine.* 1990; 22: 443-8. (Article in Japanese)
- 18) Hirayama T, Kamishima M, Eji S, et al. A case of Chronic idiopathic intestinal pseudo-obstruction supported effectively with semi-digestive nutrient alone. *Japanese Journal of Nutritional Assessment.* 1999; 16: 77-82. (Article in Japanese)

19) Matsuura A, Kikuchi Y, Ooshima T, et al. A case of Chronic idiopathic intersitnal pseudo-obstruction combined transverse colon axial torsion. J Abdom Emerg Med. 1996; 16: 1321-4. (Article in Japanese)

5. CQ5: Is radical surgical treatment recommended for the treatment of isolated hypoganglionosis, MMIHS, and CIIP?

CQ5-1: Is radical surgical treatment (other than stoma construction) recommended for the treatment of isolated hypoganglionosis?	
Recommendation: Avoiding radical surgical treatment is proposed.	
Strength of recommendation	1 (Strong): Recommend to “perform” or “not to perform” ② (Weak): Proposed to “perform” or “not to perform”
Evidence	A (Strong) B (Moderate) © (Weak) D (Very weak)

Commentary

Isolated hypoganglionosis is an allied disorder of Hirschsprung's disease that causes intestinal motility disorder despite the presence of ganglion cells in the bowel wall. The ganglion cells are congenitally small in size, and an extreme reduction in the number of ganglia plexi and ganglion cells is observed. Although there is a difference in the degree, a reduction in the number of ganglion cells is observed all across the intestinal tract. Nutrition support using central venous nutrition and enteral nutrition, and enterostomy at an appropriate site for decompression in order to prevent congestive enteritis are required in the treatment.¹⁾ The effectiveness of intestinal resection at the anal side of enterostomy has also been showed in some case reports. A systematic review showed that intestinal resection and tapering improved bowel obstruction symptoms.²⁾ However, as peristaltic disorder is observed all over the intestinal tract^{2, 3)}, radical surgery is not yet established.

References

- 1) Tuzovic L, Anyane-Yeboah K, Mills A, et al. Megacystis-microcolon-intestinal hypoperistalsis syndrome: case report and review of prenatal ultrasonographic findings. *Fetal Diagn Ther.* 2014; 36(1): 74-80.
- 2) Dingemann J, Puri P. Isolated hypoganglionosis: systematic review of a rare intestinal innervation defect. *Pediatr Surg Int.* 2010; 26: 1111-5.
- 3) Puri P, Fujimoto T. Diagnosis of allied functional bowel disorders using monoclonal antibodies and electronmicroscopy. *J Pediatr Surg.* 1988; 23: 546-54.

CQ5-2: Is radical surgical treatment (other than stoma construction) recommended for the treatment of megacystis-microcolon-intestinal hypoperistalsis syndrome (MMIHS)?				
Recommendation: Resection of dilated intestines does not improve ileus symptoms in MMIHS, so avoiding radical surgical treatment is proposed.				
Strength of recommendation	1 (Strong): Recommend to “perform” or “not to perform” ② (Weak): Propose to “perform” or “not to perform”			
Evidence	A (Strong)	B (Moderate)	C (Weak)	Ⓓ (Very weak)

Commentary

Four case reports had useful findings for this CQ. No symptom improvement has been reported. Both Martin type jejunum side-to-side anastomosis, and additional small intestinal resection and right hemicolectomy were reported not to improve the symptoms.¹⁾ Resection of the dilated segment did not improve the symptoms of abdominal distension or ileus, nor was the effectiveness of radical surgery confirmed in the literature.²⁾

References

1) Hirakawa H, Ueno S, Matuda H, et al. Effect of the herbal medicine dai-kenchu-to on gastrointestinal motility in patients with megacystis-microcolon-intestinal hypoperistalsis syndrome (MMIHS) and chronic idiopathic intestinal pseudo-obstruction (CIIP): report of two cases. Tokai J Exp Clin Med. 2009; 34: 28-33.

2) Patel R, Carty H. Megacystis-microcolon-intestinal hypoperistalsis syndrome: a rare cause of intestinal obstruction in the newborn. Br J Radiol. 1980; 53: 249-52.

CQ5-3: Is radical surgical treatment (other than stoma construction) recommended for the treatment of chronic idiopathic intestinal pseudo-obstruction (CIIP)?				
<p>Recommendation: Concomitant use of antegrade continence enema and antidromic enema is suggested for the treatment of CIIP to improve defecation.</p> <p>In cases with duodenal dilatation, duodenojejunostomy is suggested to improve the intestinal transit. It may relieve the pseudo-obstructive symptoms to some extent.</p> <p>Intestinal resection does not improve the pseudo-obstructive symptoms, so avoiding radical surgical treatment is suggested.</p>				
Strength of recommendation	<p>1 (Strong): Recommend to “perform” or “not to perform”</p> <p>② (Weak): Propose to “perform” or “not to perform”</p>			
Evidence	A (Strong)	B (Moderate)	C (Weak)	Ⓓ (Very weak)

Commentary

Six case reports had useful findings for this CQ.

Beneficial outcomes:

Antegrade continence enema improved defecation remarkably, but improved abdominal distension mildly.¹⁾ Duodenojejunostomy, in the case of duodenal dilatation, improved the transit of the dilated intestine remarkably, and improved the symptoms to some extent.²⁾ Ileocecal resection reduced the transit time of contrast medium to reach the colon in imaging examinations.³⁾

Harmful outcomes:

Ileocecal resection⁴⁾ and colectomy⁵⁾ did not improve bowel obstruction symptoms. Based on the report of surgery-related death⁶⁾, attempting radical surgery for chronic intestinal pseudo-obstruction could be harmful.

References

- 1) Kubota A, Kawahara H, Hasegawa T, et al. Surgical treatment for Chronic constipation. Japanese Journal of Pediatric Surgery. 2008; 40: 226-34. (Article in Japanese)
- 2) Amano Y, Nakahata R, Akahane T. Cases of siblings with Chronic idiopathic intestinal pseudoobstruction (CIIP). The Journal of Pediatric Practice. 1985; 48: 937-41. (Article in Japanese)
- 3) Nishina M, Kido N, Fujii C, et al. Surgical experience of Chronic idiopathic intestinal pseudo-obstruction. Hukubuiryo no shinpo. 1987; 7: 635-9. (Article in Japanese)
- 4) Nozawa H, Hori T, Kubo K. An older child with chronic idiopathic intestinal pseudo-obstruction presenting chronic constipation – problems on diagnosis. Japanese Journal of Pediatric Surgery. 1983; 15: 1135-8. (Article in Japanese)
- 5) Ozawa M, Yamada R, Oohama M. Two cases of Chronic Idiopathic Intestinal Pseudo-obstruction Syndrome(CIIPS). Japanese Journal of Pediatric Surgery. 1983; 15: 1139-46. (Article in Japanese)
- 6) Dalgic B, Sari S, Dogan I, et al. Chronic intestinal pseudoobstruction: report of four pediatric patients. Turk J Gastroenterol. 2005; 16: 93-7.

6. CQ6: Is small bowel transplantation recommended for the treatment of isolated hypoganglionosis, MMIHS, and CIIP?

CQ6-1: Is small bowel transplantation useful for the treatment of isolated hypoganglionosis?				
Recommendation: Small bowel transplantation is proposed for the treatment of isolated hypoganglionosis, as it may be useful for the following cases: patients in whom discontinuing parenteral nutrition (PN) is difficult even after the maximum use of the native intestinal tract under intestinal rehabilitation; patients in whom the number of central venous access routes is lacking; patients with repeated episodes of sepsis; and patients with progressive hepatopathy.				
Strength of recommendation	1 (Strong): Recommend to “perform” or “not to perform” ② (Weak): Propose to “perform” or “not to perform”			
Evidence	A (Strong)	B (Moderate)	C (Weak)	Ⓓ (Very weak)

Commentary

According to the Intestinal Transplant Registry, small bowel transplantation was performed in 2,600 cases or more by 2011 all over the world. Among them, patients with motility disorder as primary disease accounted for 15% of adults and 19% of children. In Japan, the first small bowel transplantation was performed in 1996, and 26 transplantations in 23 cases were performed by 2014. The postoperative patient survival and graft survival rates at 1, 5, and 10 years are 87%, 68%, 58%; and 80%, 59%, 44%, respectively. The short-term results are relatively good, but the long-term prognosis is still poor.¹⁾

Articles from overseas regarding small bowel transplantation for isolated hypoganglionosis cannot be found, probably because there are no common worldwide diagnostic criteria. Only one case from Tohoku University has been addressed in papers.^{2, 3)} A 14-year-old boy who had a history of 10 laparotomies was experiencing progressive difficulty with oral intake due to multiple stenoses of the small bowel secondary to repeated enteritis and abdominal pain, and a progressive lack of central venous access routes. The patient reportedly achieved successful oral intake after the transplantation, which led to discontinuing parenteral nutrition and being discharged.^{4, 5)}

The following five institutions have performed small bowel transplantation: Kyoto University, Osaka University, Tohoku University, Keio University, and Kyushu University. An overview of small bowel transplantation cases for hypoganglionosis in Japan as of January 2016 based on a report from the Japanese Intestinal Transplantation Registry and confirmation with the transplantation institutions is shown in **Table 6**. Nine small bowel transplantations (living donors: 6, brain-dead donors: 3) in 8 cases have been performed so far; the patient survival was 7/8 (88%), and the graft survival was 5/9 (56%). Among the 5 cases of graft survival, complete discontinuation without requiring any transfusion at all was achieved in 3/5 (60%) cases, and 2/5 (40%) cases temporarily or always required transfusion. Stoma closure was performed in 1/5 (20%) cases; partial closure, such as Bishop-Koop and Santulli, was performed in 2/5 (40%) cases; and 2/5 (40%) cases remained open.

Small bowel transplantation for isolated hypoganglionosis has been performed in cases where disease management is difficult due to a lack of central venous access or repeated episodes of sepsis. While there are patients who benefitted from transplantation, such as achieving successful oral intake and a reduced dependency on parenteral nutrition, acute rejection and chronic rejection may result in graft removal in

many cases. Given that the graft survival rate has remained at 56%, we should carefully determine the indications of small bowel transplantation as a surgical treatment for isolated hypoganglionosis, and establishing control with the patient's own intestine should be given the highest priority.

References

- 1) Ueno T, Matsuura T, Fukuzawa M, et al. Report on the cases of small intestinal transplantation in Japan. *Japanese Journal of Transplantation*. 2015; 50: 191-5. (Article in Japanese)
- 2) Ishii T, Wada M, Nishi K, et al. Living-related intestinal transplantation for a patient with hypoganglionosis. *Pediatr Transplant*. 2006; 10: 244-7.
- 3) Ishii T, Wada M, Nishi K, et al. Two cases of living-related intestinal transplantation. *Transplant Proc*. 2006; 38: 1687-8.
- 4) Wada M, Ishii T, Kato T, et al. Living-related small bowel transplantation: two cases experiences. *Transplant Proc*. 2005; 37(2): 1381-2.
- 5) Wada M, Ishii T, Kato T, et al. Experiences of two cases with Living small intestinal transplantation. *Transplantation Now*. 2005; 18: 145-51. (Article in Japanese)

Table 6. Cases of small bowel transplantation for isolated hypoganglionosis in Japan

Table. Cases of small bowel transplantation for hypoganglionosis in Japan

Case	Year of transpl	Institution	Age	Sex	Indication for transplantation	Living/Brain-dead	Patient survival	Graft survival	PN	Stoma
1	2003	Tohoku University	14	Male	Repeated sepsis	Living	Survival	Survival	lete discontinu	Partial opening
2	2006	Keio University	14	Male	PN dependence, Lack of central venous access	Living	Survival	Survival	lete discontinu	Partial opening
3	2007	Keio University	11	Male	PN dependence, Lack of central venous access	Living	Survival	Survival	ial discontinua	Partial opening
4	2007	Tohoku University	28	Female	Repeated sepsis, Lack of central venous access	Living	Survival	Resection (ACR)	Dependence	Partial opening
4'	2007	Tohoku University	27	Female	Graft failure due to ACR	Brain-dead	Survival	Resection (CR)	Dependence	After graft removal (Partial opening before removal)
5	2011	Keio University	13	Male	PN dependence, Lack of central venous access	Living	Survival	Resection (CR)	Dependence	After graft removal (Opening before removal)
6	2011	Kyoto University	10	Female	Hepatopathy, Nutritional deficiency, CRBSI	Brain-dead	Death	Patient death	Dependence	Opening
7	2013	Tohoku University	20	Male		Brain-dead	Survival	Survival	lete discontinu	Opening
8	2014	Keio University	10	Male	Repeated sepsis, Lack of central venous access	Living	Survival	Survival	ial discontinua	Opening

Case 4' is the re-transplantation case of case 4.

CQ6-2: Is small bowel transplantation useful for megacystis-microcolon-intestinal hypoperistalsis syndrome (MMIHS)?				
Recommendation: Small bowel transplantation is proposed for cases not complicated with liver or renal failure. Multiple organ transplantation is proposed for cases complicated with liver or renal failure.				
Strength of recommendation	1 (Strong): Recommend to “perform” or “not to perform” ② (Weak): Propose to “perform” or “not to perform”			
Evidence	A (Strong)	B (Moderate)	C (Weak)	Ⓓ (Very weak)

Commentary

MMIHS is the most serious type of diseases presenting with functional ileus. In many cases, the symptoms develop from an early stage after birth with a poor prognosis.¹⁾ The associated causes of death include sepsis, malnutrition, hepatic failure, renal failure, and multiple organ failure, and no specific method of treatment has been established.^{2, 3)}

Small bowel transplantation for MMIHS has never been performed in Japan (as of January 2016). Papers on organ transplantation have been reported only from overseas, and most of the cases reported are multiple organ transplantations including the stomach, small bowel, colon, liver, pancreas, and kidney, as hepatic failure and renal failure are accompanied at the time of transplantation in the majority of reported cases.^{1, 2, 4-6)} There is one case report of an eight-year-old girl without hepatic or renal failure at the time of transplantation, and isolated small bowel transplant helped her to achieve oral intake.⁷⁾ Another case describes a one-year-old girl who successfully received combined living donor liver/small bowel transplantation from her mother.⁸⁾ In multiple organ transplantation, there are many cases in which the stomach is simultaneously transplanted to prevent postoperative gastric motility disorder. However, in cases of isolated small bowel transplantation and combined living donor liver/small bowel transplantation, the postoperative gastric emptying function was improved in both cases, and it has been suggested that the stomach does not necessarily need to be transplanted simultaneously.

The patient and graft survival rates after small bowel transplantation are poor in the long term. However, considering the otherwise extremely poor prognosis of MMIHS, multiple organ transplantation historically only being performed overseas, and the difficulties of combined liver/small bowel transplantation in Japan, isolated small bowel transplantation might be useful when the disease is not complicated with hepatic failure. This is the current situation of small bowel transplantation for MMIHS in Japan.

References

1) Loinaz C, Rodríguez MM, Kato T, et al. Intestinal and multivisceral transplantation in children with severe gastrointestinal dysmotility. *J Pediatr Surg.* 2005; 40: 1598-604.
2) Gosemann JH, Puri P. Megacystis microcolon intestinal hypoperistalsis syndrome: systematic review of outcome. *Pediatr Surg Int.* 2011; 27: 1041-6.

- 3) Puri P, Shinkai M. Megacystis microcolon intestinal hypoperistalsis syndrome. *Semin Pediatr Surg.* 2005; 14: 58-63.
- 4) Masetti M, Rodriguez MM, Thompson JF, et al. Multivisceral transplantation for megacystis microcolon intestinal hypoperistalsis syndrome. *Transplantation.* 1999; 68: 228-32.
- 5) Nathan JD, Rudolph JA, Kocoshis SA, et al. Isolated liver and multivisceral transplantation for total parenteral nutrition-related end-stage liver disease. *J Pediatr Surg.* 2007; 42: 143-7.
- 6) Pohl J, Chandra R, Corpuz G, et al. Hypertriglyceridemia and megacystis-microcolon-intestinal hypoperistalsis syndrome. *J Pediatr Gastroenterol Nutr.* 2008; 47: 507-13.
- 7) Huang CM, Tseng SH, Weng CC, et al. Isolated intestinal transplantation for megacystis microcolon intestinal hypoperistalsis syndrome: case report. *Pediatr Transplant.* 2013; 17: E4-8.
- 8) Raofi V, Beatty E, Testa G, et al. Combined living-related segmental liver and bowel transplantation for megacystis-microcolon-intestinal hypoperistalsis syndrome. *J Pediatr Surg.* 2008; 43: e9-e11.

CQ6-3: Is small bowel transplantation useful for chronic idiopathic intestinal pseudo-obstruction (CIIP)?				
Recommendation: Small bowel transplantation for the treatment of CIIP is proposed, as it may be useful for the following cases: patients whose symptoms remain intolerable even with adequate parenteral nutrition, enteral nutrition, and gastrointestinal decompression therapy; patients in whom the number of central venous access routes is lacking; and patients with repeated episodes of sepsis. The possible impairment of the native gastric outlet function needs to be considered when small bowel transplantation is planned and performed.				
Strength of recommendation	1 (Strong): Recommend to “perform” or “not to perform” ② (Weak): Propose to “perform” or “not to perform”			
Evidence	A (Strong)	B (Moderate)	C (Weak)	Ⓓ (Very weak)

Commentary

CIIP is a functional bowel obstruction with an unknown etiology. Treatment may start with conservative treatments, such as drug therapy and intravenous and enteral nutrition, and then shift to invasive treatments, such as decompression by tubing or enterostomy, as the condition progresses. In the cases in which intolerable pain is present despite these treatments, and in which the disease is complicated by a lack of central venous access or repeated episodes of sepsis, small bowel transplantation may be performed as a final measure.

Since this disease is often characterized by disorder of gastric emptying, multiple organ transplantation including the stomach has been generally performed overseas.^{1, 2)} A group from the University of Bologna in Italy performed transplantation in 11 cases with CIPO accompanied by functional disorder of gastric emptying. Multiple organ transplantation was performed only for two cases, and for the remaining nine cases, isolated small bowel transplantation and partial gastrectomy with graft-gastric and graft-duodenal anastomoses were performed.³⁾ In 6 (86%) out of the 7 surviving cases, oral intake was enabled, and in 5 cases (71%), gastric emptying was normalized.

In Japan, small bowel transplantation for CIIP has been performed in three cases. In two of these cases, two anastomoses were performed at the oral side to add graft-duodenal or graft-jejunal anastomosis to graft-gastric anastomosis. In both cases, however, oral intake was not easily established. Only one out of the three cases has survived.

CIIP is an intractable disease with an unknown etiology for which an effective treatment method has not yet been established. Small bowel transplantation may be the only therapy for severe cases, but the oral intake is not easily established after transplantation. As for the current situation regarding small bowel transplantation for CIIP in Japan, multiple organ transplantation is not feasible. Isolated small bowel transplantation should be provided carefully with close consideration of the appropriate anastomosis approach for ensuring the gastric emptying function in each case.

References

- 1) Loinaz C, Mittal N, Kato T, et al. Multivisceral transplantation for pediatric intestinal pseudo-obstruction: single center's experience of 16 cases. *Transplant Proc.* 2004; 36: 312-3.

- 2) Sigurdsson L, Reyes J, Kocoshis SA, et al. Intestinal transplantation in children with chronic intestinal pseudo-obstruction. *Gut*. 1999; 45: 570-4.
- 3) Lauro A, Zanfi C, Pellegrini S, et al. Isolated intestinal transplant for chronic intestinal pseudo-obstruction in adults: long-term outcome. *Transplant Proc*. 2013; 45: 3351-5.

7. CQ7: What is the prognosis of isolated hypoganglionosis, MMIHS, and CIIP?

CQ7-1: What is the prognosis of isolated hypoganglionosis?

Recommendation: Long-term survival can be expected with appropriate treatment. In many cases, adequate nutritional support and intestinal stoma care are required for a long period of time.

Evidence	A (Strong)	B (Moderate)	Ⓒ (Weak)	D (Very weak)
----------	------------	--------------	----------	---------------

Commentary

In article of a systematic review¹⁾, multidisciplinary treatment improved the survival rate from 12.6% in 1977 to 55.6% in 2011. When patients receive appropriate therapy, a longer survival can be expected. Of these cases, there are some in which disease control was obtained with oral intake alone, in which normal growth or only mild growth disorder was observed, and in which school attendance was achieved. However, many cases may require long-term management of nutrition and enterostomy.

References

- 1) Friedmacher F, Puri P. Classification and diagnostic criteria of variants of Hirschsprung's disease. *Pediatr Surg Int.* 2013; 29: 855-72.

CQ7-2: What is the prognosis of megacystis-microcolon-intestinal hypoperistalsis syndrome (MMIHS)?

Recommendation: Patients with MMIHS have a poor prognosis in comparison to healthy children; however, long-term survival can be expected with appropriate treatment. In many cases, adequate nutritional support and intestinal stoma care are required, and the functional prognosis is poorer than that of healthy children.

Evidence	A (Strong)	B (Moderate)	Ⓒ (Weak)	D (Very weak)
----------	------------	--------------	----------	---------------

Commentary

A cross-sectional study in Japan showed that 10 out of 19 cases were surviving and 9 cases were dead, with a 5-year survival rate of 62.8% and 10-year rate of 56.5%. The main causes of death were hepatic failure and sepsis. In 2 systematic reviews, the number of surviving cases was 43 out of 218 cases¹⁾ and 23 out of 182 cases²⁾, indicating that this disease is a serious condition with a poor prognosis. Its poor prognosis has often been reported in case reports and case-series. The age of death ranges from immediately after birth to 15 years old, and about 80% die in infancy (<1 year after birth).

Among case reports, we found a report on an infant who successfully self-defecated and self-urinated at the age of 1 year and 10 months³⁾ and another report on an infant who successfully achieved a normal intake at the age of 2 years and 6 months.⁴⁾ The physical and mental development of children with MMIHS has been reported to be delayed in one report⁵⁾ and normal in another.³⁾ Two reports have described patients starting school under home parenteral nutrition.^{5, 6)}

References

- 1) Gosemann JH, Puri P. Megacystis microcolon intestinal hypoperistalsis syndrome: systematic review of outcome. *Pediatr Surg Int.* 2011; 27: 1041-6.
- 2) Puri P, Shinkai M. Megacystis microcolon intestinal hypoperistalsis syndrome. *Semin Pediatr Surg.* 2005; 14: 58-63.
- 3) Shimizu H, Ise K, Yamashita K, et al. A case of Megacystis- microcolon-intestinal hypoperistalsis syndrome successfully treated with surgery. *J. Jpn. Soc. Pediatr. Surg.* 2013; 49: 1117-21. (Article in Japanese)
- 4) Kubo M, Sanbonmatsu T. A case of Megacystis-Microcolon-Intestinal Hypoperistalsis Syndrome (Incompetent type) underwent fetal bladder puncture. *Japanese Journal of Pediatric Surgery.* 1997; 29: 1351-6. (Article in Japanese)
- 5) Hirato J, Nakazato Y, Koyama H, et al. Encephalopathy in megacystis-microcolon-intestinal hypoperistalsis syndrome patients on long-term total parenteral nutrition possibly due to selenium deficiency. *Acta Neuropathol.* 2003; 106:234-42.
- 6) Oohama M, Take H, Yamamot H, et al. Allied disorders of Hirschsprung's disease – clinical course of Chronic Idiopathic Intestinal Pseudo-obstruction Syndrome (CIIPS); Surgical complications and super long-term central venous nutrition. *Japanese Journal of Pediatric Surgery.* 1996; 28:1073-8. (Article in Japanese)

CQ7-3: What is the prognosis of chronic idiopathic intestinal pseudo-obstruction (CIIP)?				
Recommendation: The actual prognosis of CIIP developed in childhood is not poor; however, adequate nutritional support and intestinal stoma care are required for a long period in many cases. The functional prognosis of CIIP is poor.				
Evidence	A (Strong)	B (Moderate)	© (Weak)	D (Very weak)

Commentary

In Japan, out of 62 cases of children with CIPO, only 4.8% (3 out of 62 cases) died of enteritis or sepsis, and the prognosis of children CIPO seems to be relatively good. However, long-term central venous nutrition management is required for life support, and their quality of life is accordingly limited.

In a questionnaire survey of 45 cases at 1 to 21 years of age, 38% of the cases depended on parenteral nutrition, 17% on enteral nutrition via tube, and 4% on parenteral nutrition with enteral nutrition via tube. In other case series and case reports, many patients depended on parenteral nutrition, and their functional prognosis was poorer than that of healthy people.

The physical development was reported to be normal at 2¹⁾ and 8 years of age.²⁾

Regarding school and work, situations of CIPO patients to be equivalent to those of healthy people in three out of four cases³⁾, and another showed that schooling was equivalent in two out of three cases; in one case, however, the patient was in a class for handicapped children.⁴⁾

References

1) Tazuki Y, Wasa M, Fukuzawa M. 【Learn allied disorders of Hirschsprung’s disease】 A case of MMIHS under management of TPN supplemented with enteral nutrition via enterostomy. Japanese Journal of Pediatric Surgery. 2006; 38:715-9. (Article in Japanese)

2) Yahano S, Furuya S, Kadowaki H. A 8-year-old girl with CIIP – clinical course and problems on long-term TPN. Japanese Journal of Pediatric Surgery. 1983; 15:1129-33. (Article in Japanese)

3) Terui K, Yoshida H. 【Today’s progress in Home parenteral nutrition】 (Part-7) Nutritional management at Home for shortbowel syndrome – Cases with intestinal failure requiring long-term central vein nutrition. Rinsho Eiyo (JCN selection 8 Home parenteral and enteral nutrition- Today’s progress). 2013; suppl: 204-8. (Article in Japanese)

4) Ootu K, Furuta Y, Onitake M. 【Learn allied disorders of Hirschsprung’s disease】 Experiences of 3 caces with intractable allied disorders of Hirschsprung’s disease. Japanese Journal of Pediatric Surgery. 2006; 38: 729-36. (Article in Japanese)

VII. Planning after public release

1. Organization after public release

Name of organization	Actions after public release
Guideline steering committee	<p>The representative of this guideline steering committee shall belong to the Department of Pediatric Surgery, Faculty of Medical Sciences, Kyushu University. This guideline is planned to be revised five years after public release, and the organization for the revision group will be re-organized mainly by the Department of Pediatric Surgery, Faculty of Medical Sciences, Kyushu University.</p> <p>When the committee recognizes the need to modify the recommendation statements substantially, it will reconvene the guideline development group, announce a temporary stop of the usage or revision on the website after discussion, and conduct a complete revision. The expiration of the guideline will be discussed with the guideline development management office and the guideline development group.</p>
Guideline development group	<p>The group will publicly release this guideline on the homepages of the research partner institutions. When revision is required, it will be reported to the steering committee for discussion. Furthermore, when a revision is conducted in five years, the members will answer the steering committee's call to cooperate for the organization of the revision committee.</p>
SR team	<p>This team will be broken up at the completion of this guideline. However, when this guideline is revised in the future, the team members will cooperate with the revision group to provide as much advice as possible based on their experience in the guideline development.</p>

2. Introduction

Creation of summary version	<p>The detailed version will be published in research reports and distributed to major institutions. The practical version will be published as a book so that it may be utilized in daily clinical practice.</p>
Proactive use of wide range of information media	<p>The practical version will be released for free (on the Japanese Society of Pediatric Surgeons homepage, the Japanese Society for Pediatric Gastroenterology, Hepatology and Nutrition homepage, Minds homepage, this guideline's management office homepage, Research partner institutions' homepage). Furthermore, media outlets, such as newspapers, magazines, and the Internet, will be used to increase the public recognition.</p>
Promoting and inhibiting factors for the effective use of the clinical practice guideline	<p>(Promoting factors) Increase in public recognition, establishment of a family association, establishment of a social security system, and consolidation of cases</p> <p>(Inhibiting factors) Conventional medical practices</p>

3. Evaluation of effectiveness

Evaluation method	Specific policies
Retrospective study	<p>A nationwide survey on the short and long-term outcomes of the cases after the public release of this guideline is to be conducted, and the outcomes will be reexamined using historical controls.</p>

Prospective study	Standardization of treatments based on this guideline and a prospective, multi-center study to evaluate the effectiveness are to be conducted.
-------------------	--

4. Revision

Items	Policy
Period of implementation	Revision is expected five years later (2021).
Method of implementation	The guideline steering committee will organize a guideline revision group. However, if no financial support from related medical societies or the Research Project on Measures for Intractable Diseases of Ministry of Health, Labour and Welfare is obtained, reexamination is required.
Organization of implementation	The guideline steering committee of this guideline and the guideline development group will cooperate to reorganize a guideline revision group.